EUROVALVE

CROWNE PLAZA LINATE

MILAN

SEPTEMBER 21&22,2023

COURSE DIRECTORS

Patrizio Lancellotti, Belgium
Khalil Fattouch, Italy
Gilbert Habib, France
José Luis Zamorano, Spain
Philippe Pibarot, Canada
Mani Vannan, USA
Jeroen Bax, The Netherlands

LOCAL HOST

Eustachio Agricola, Italy

EUROVALVE
CROWNE PLAZA LINATE
MILAN

SEPTEMBER
21&22,2023

Alternative Routes in Question(s)

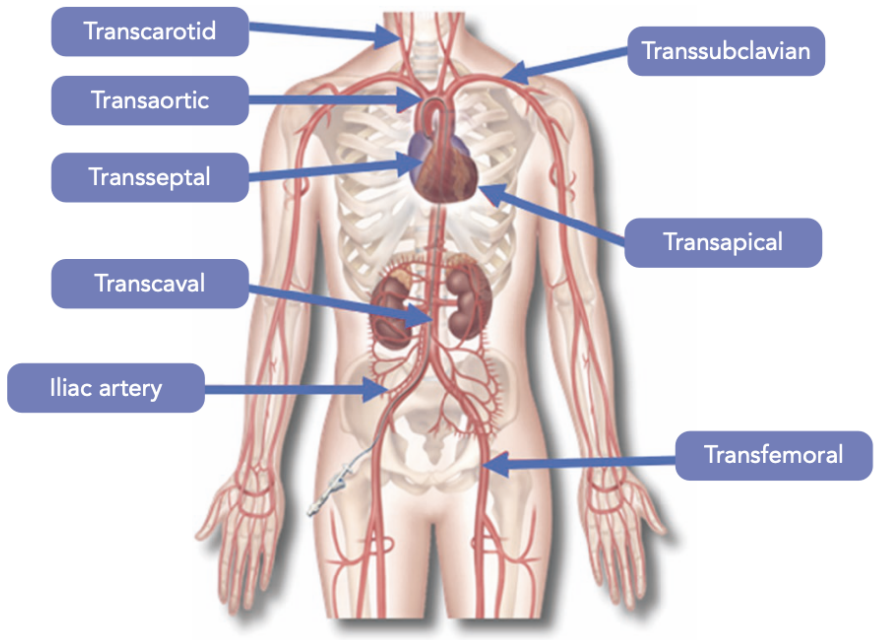

LIÈGE université

Mathieu LEMPEREUR, MD, PhD

CHU de Liège

FACULTY DISCLOSURE

I have no financial relationships to disclose

WHEN

should we use an alternative access (AA)?

Transfemoral = KING of All Access

Why is TF the favourite route?

Outcomes

- **Less invasive**
- Better **outcomes** than alternative routes
- Early ambulation and early discharge rates

In Practice

- More practical and ergonomic in the cathlab/OR
- Less radiation exposure to the operator

Guidelines

Invasiveness:

- General Anesthesia (and mechanical ventilation)
- Surgical Cutdown
- Vascular/Heart lesion required for delivery system crossing
- Impact on other major systems (cerebral, respiratory, renal systems) *or* previous revascularisation procedures (grafts, stents)

Transfemoral: moving borders

- <u>TF limitations</u>: small artery size, extensive calcifications, severe tortuosity and combinations of these factors; prior endovascular stenting

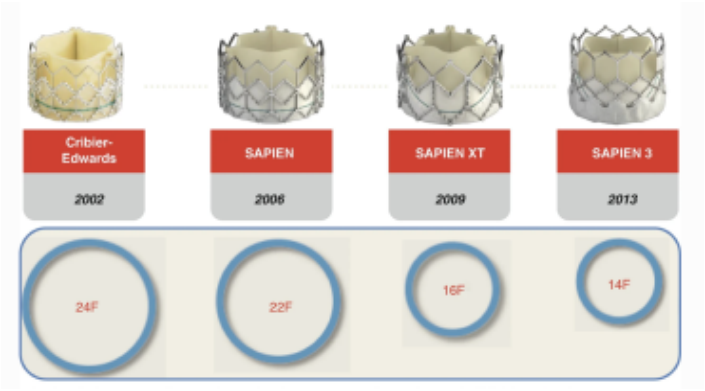

Evolution of devices: **low-profile delivery systems**, very flexible systems

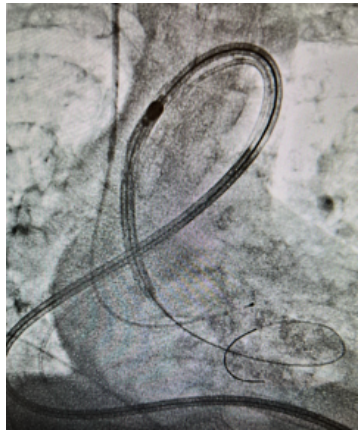

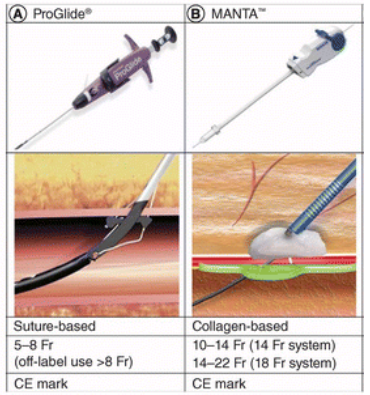

Evolution of vascular closure devices and technique

Doppler-guided femoral puncture

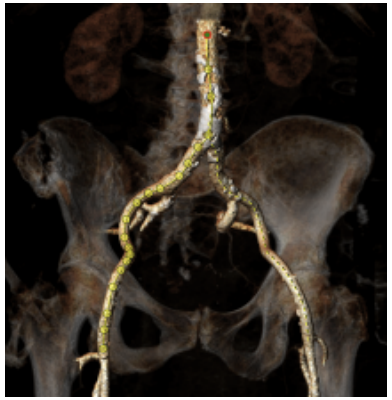

Pre-procedural planning: MSCT

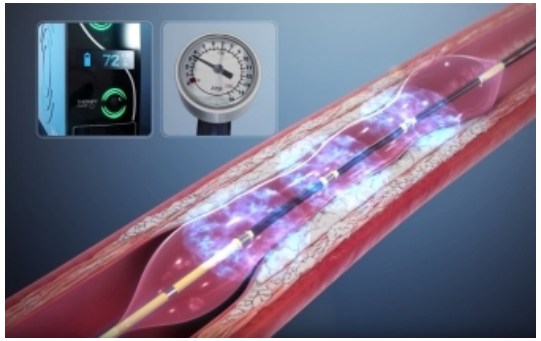

Management of peripheral artery disease (balloon angioplasty, Intravascular lithotripsy, stenting)

Management of potential complications (stents, covered stents)

Limits? Definitions?

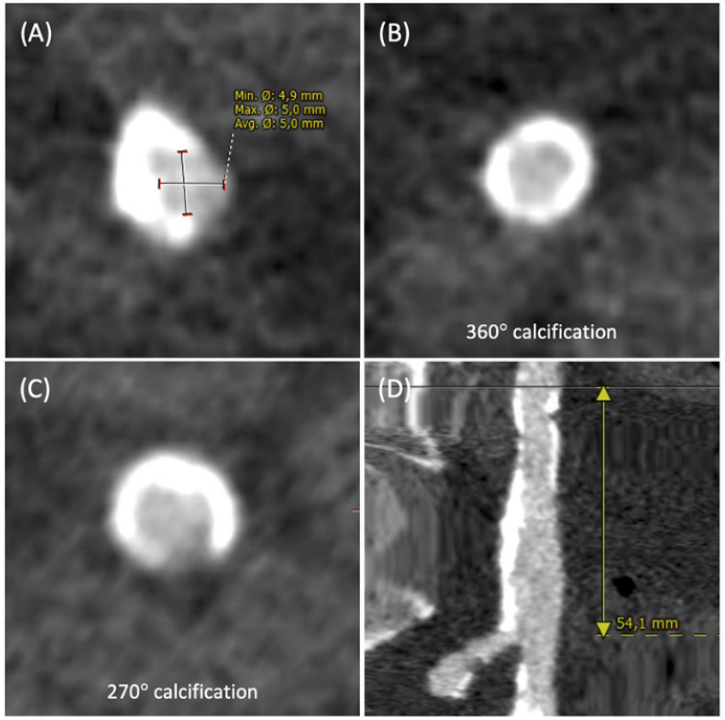

CT-based recommendations on feasibility of IVL-assisted TF-TAVI

--- Institutional Copenhagen recommendations ---

In case of local calcified stenosis < 20 mm length

- 360° calcified circumference with minimum lumen diameter ≥ 4.0 mm
- 270° calcified circumference with minimum lumen diameter ≥ 3.0 mm

In case of more diffuse calcified vessel > 20 mm length

- 360° calcified circumference with minimum lumen diameter ≥ 4.5 mm
- 270° calcified circumference with minimum lumen diameter ≥ 3.5 mm

CT, computed tomography; IVL, intravascular lithotripsy; TF-TAVI, transfemoral transcatheter aortic valve implantation.

Sawaya F. et al. Front Cardiovasc Med. 2021;22;8:739750.

CENTRAL ILLUSTRATION: Transcatheter Aortic Valve Replacement Outcomes in Patients With PAD

Severity of PAD and Outcomes Among TAVR Patients: The Hostile Registry

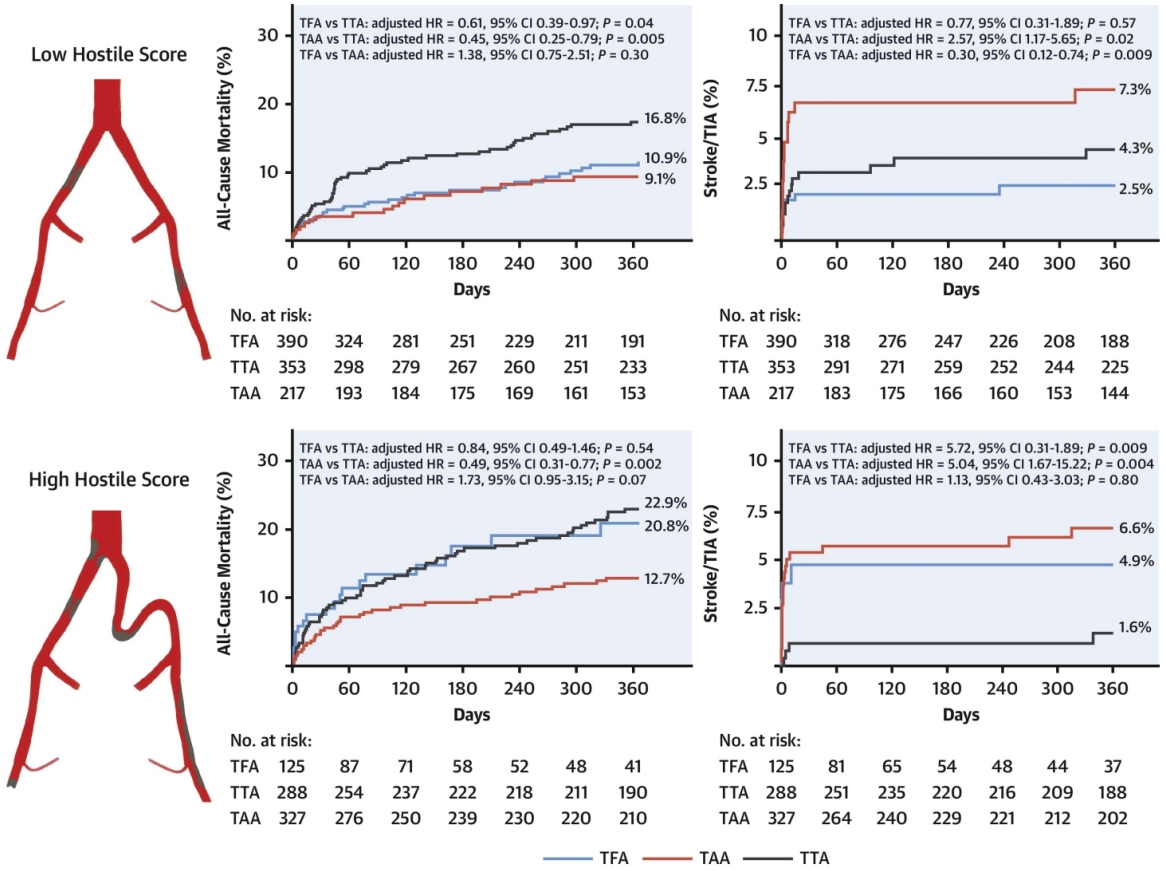

Palmerini T, et al. J Am Coll Cardiol Intv. 2023;16(4):396–411.

WHAT

do the Guidelines recommend?

Transfemoral = Gold Standard

- Most RCT in TAVI via TF
- Non-TF TAVI: higher mortality (access + higher comorbidity and risk)

2021 ESC/EACTS

SAVR is recommended in younger patients who are low risk for surgery (<75 years[e] and STS-PROM/EuroSCORE II <4%)[e,f], or in patients who are operable and unsuitable for transfe-moral TAVI.[244]	I	B
Non-transfemoral TAVI may be considered in patients who are inoperable and unsuitable for transfemoral TAVI.	IIb	C

2020 ACC/AHA

1	A

6. For patients with an indication for AVR for whom a bioprosthetic valve is preferred but valve or vascular anatomy or other factors are not suitable for transfemoral TAVI, SAVR is recommended (1–3,11).

Otto C et al. J Am Coll Cardiol. 2021,77(4):e25–e197.
Vahanian et al. *European Heart Journal*, 2022,43(7):561–632

HOW OFTEN

do we need/use an alternative route?

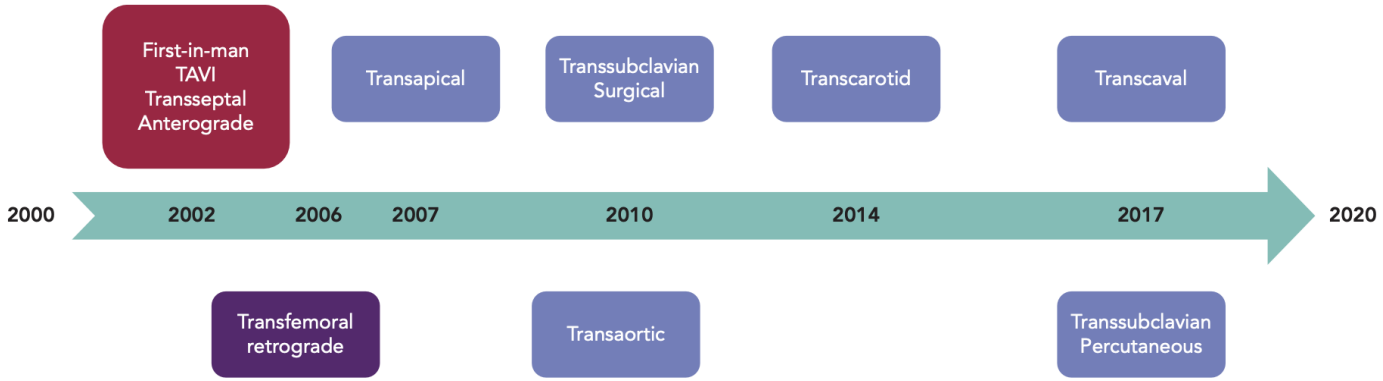

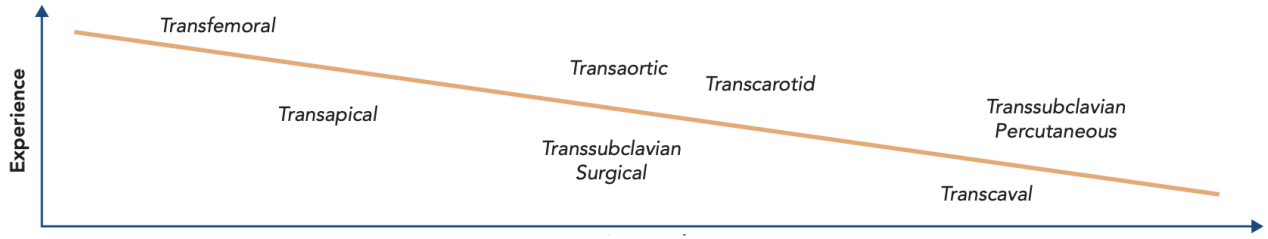

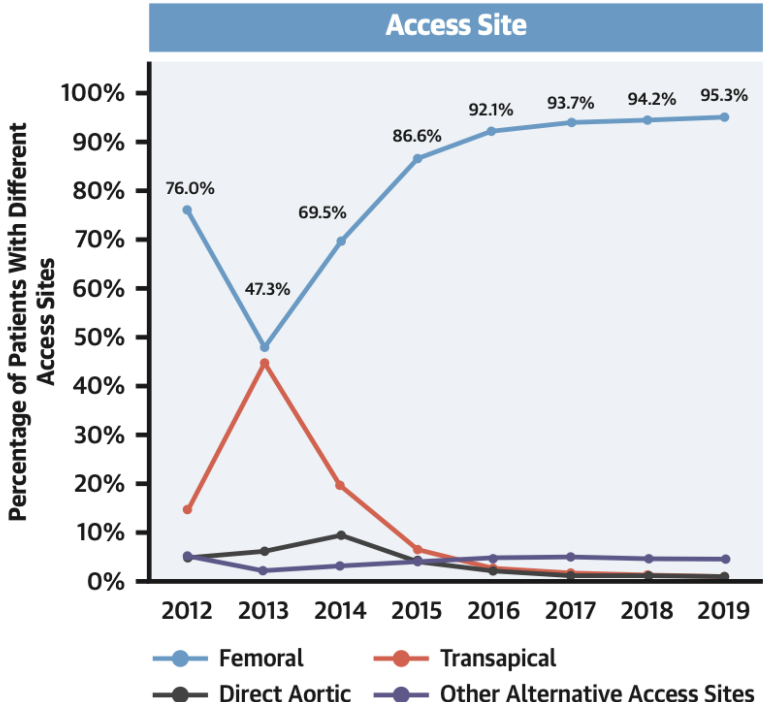

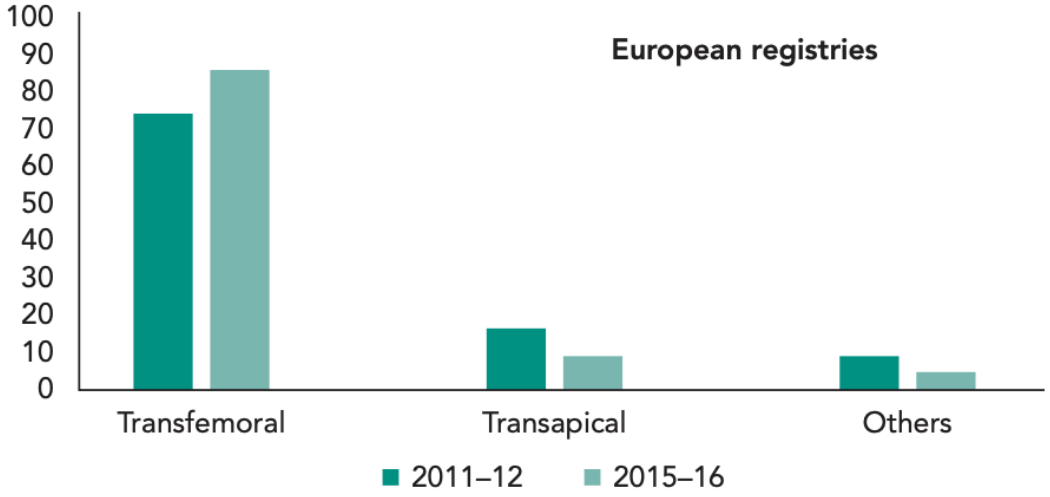

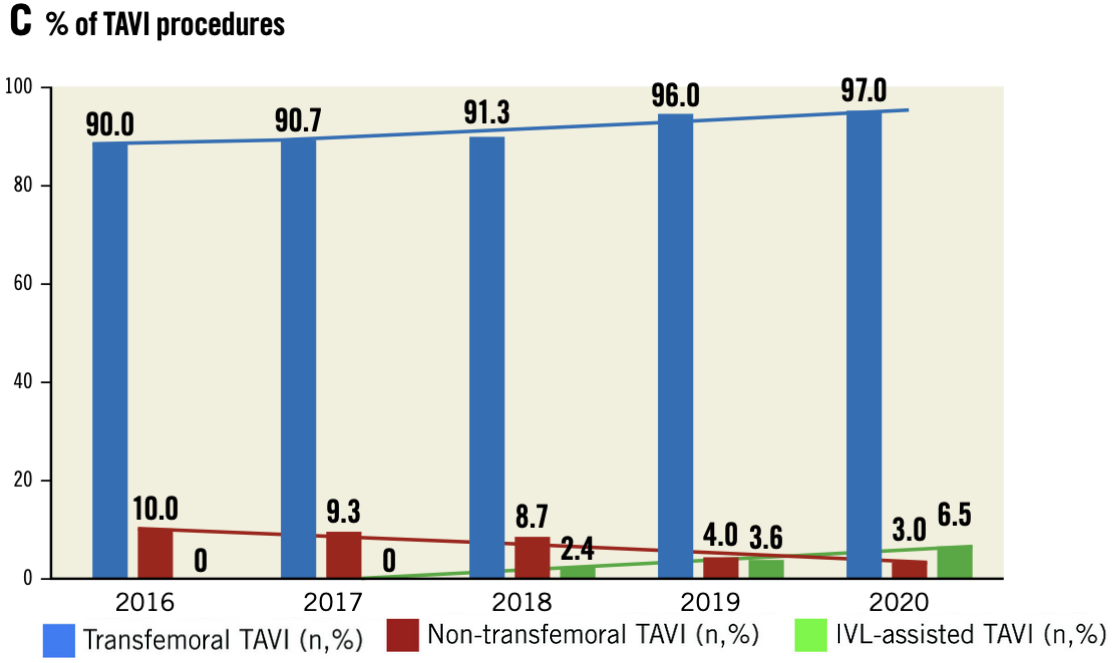

Overtchouk P et al. Interv Cardiol. 2018 Sep;13(3):145-150.
Carroll JD et al. J Am Coll Cardiol. 2020;76(21):2492-2516.
Nardi G et al. EuroIntervention. 2022;17(17):e1397-e1406.

WHICH

access should we chose?

Choice of Alternative Access (AA)

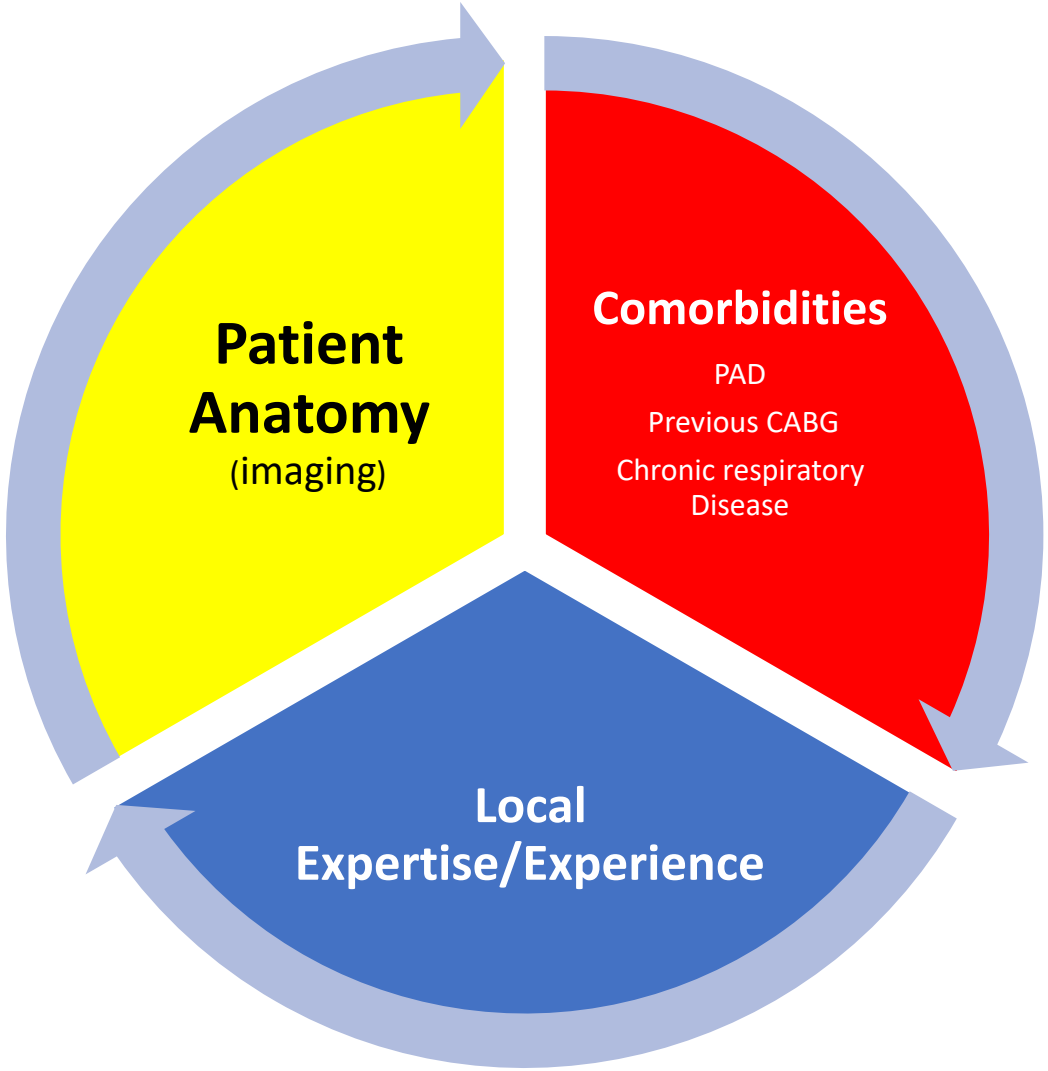

- Limited data from randomized trials comparing AA vs SAVR or between AA
- Direct comparison of outcomes between TF and AA or between AA is difficult
  - Severe comorbidities
  - Higher procedural risk

Ideal alternative pathway

- *Percutaneous*
- *Conscious sedation and local anesthesia*
- *Favourable operating room ergonomics and adapted THV material*
- *Similar resulsts to TF (mortality, major bleeding, stroke)*

Overtchouk P et al. Interv Cardiol. 2018 Sep;13(3):145-150.
Perrin N et al. Front. Cardiovasc. Med. 8:747583.
Lanz J et al. EuroIntervention 2018;14:AB40-AB52

Transseptal Access

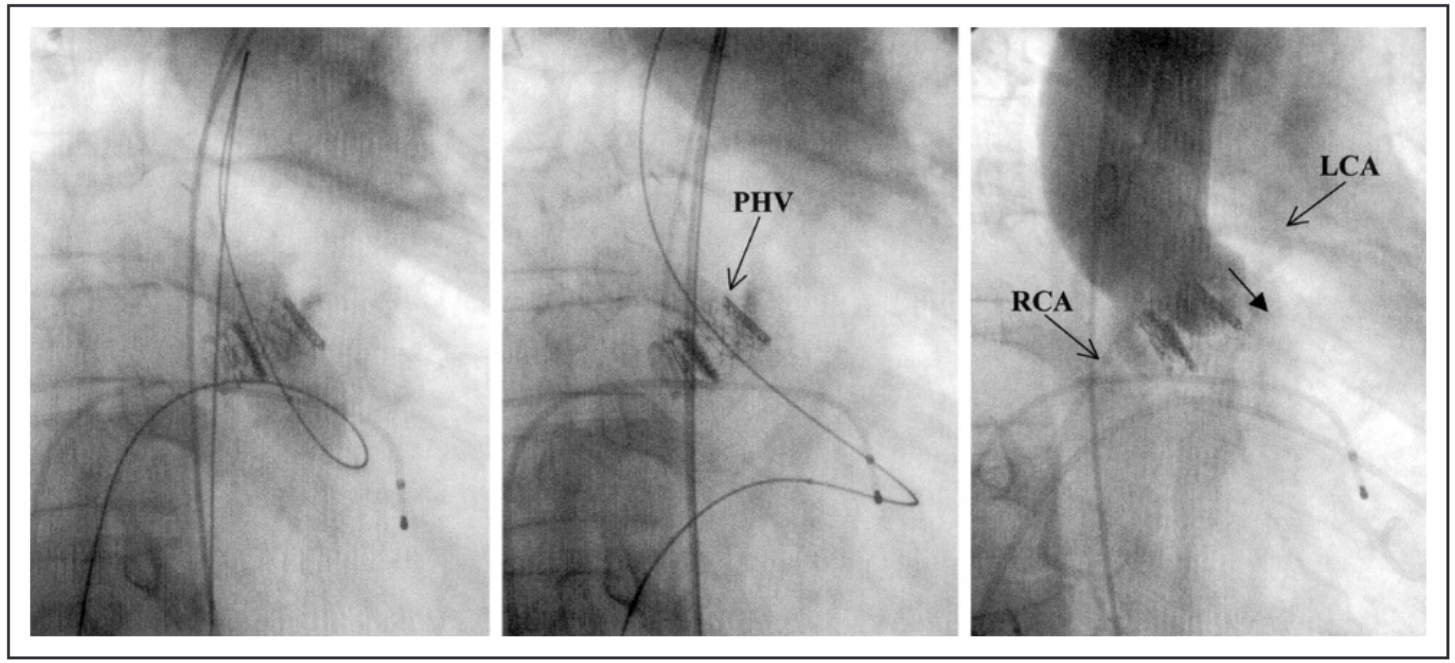

Figure 2. PHV delivery within the native calcific valve. Left, Maximal balloon inflation (23 mm) for valve delivery. Middle, The PHV in position at mid part of the native aortic valve, pushing aside the calcific leaflets. Right, Supraaortic angiogram after PHV implantation showing no aortic regurgitation across the PHV and a mild paravalvular regurgitation (arrow). Both coronary ostia are patent and removed from the valve prosthesis. LCA indicates left coronary artery; RCA, right coronary artery.

Cribier A et al. Circulation. 2002;106(24):3006-8.

Transthoracic Approaches: Last Resort?

- Stay away from the chest!
  - No chest wall injury
  - No entry in pleural cavity
  - Rapid recovery

  - Higher mortality and bleeding complications
    - Higher baseline risk of selected patients
    - More invasive

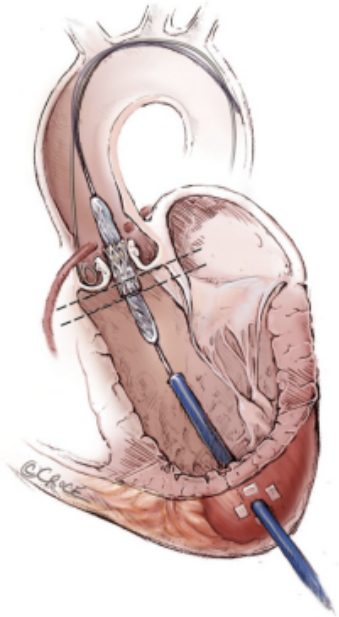

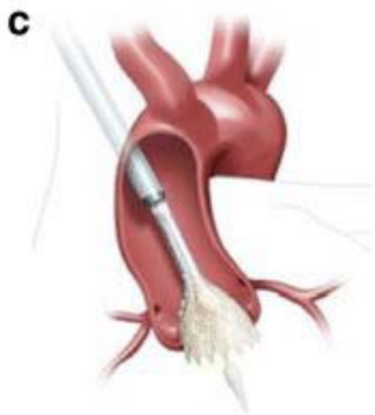

Transapical

- First alternative access described and only anterograde pathway
- Excellent controllability and easy valve crossing
- Invasive, High rate of mortality and major bleeding
- Inferiority to other pathways and open surgery in the elderly and lower-risk patients
- Progressively abandonned

Transaortic

- Excellent controllability and precise THV positioning
- High rates of life-threatening bleeding
- Possible superiority over TA access but not against TF

Blackstone E et al. Circulation 2015; 131:1989–2000.
Frohlich G et al. Am J Cardiol. 2015;116:1555–9.
O'Hair D et al. Ann Thorac Surg.2018;105:484–90.

Transcarotid Access (TC)

- Surgical access: common carotid artery; surgical repair
- Left-side favoured for aortic root alignment; Right-side: unfavourable alignment if steep angle between annular plane and aorta axis
- CS+LA/GA: team dependent
- Fast ambulation and short hospital stay

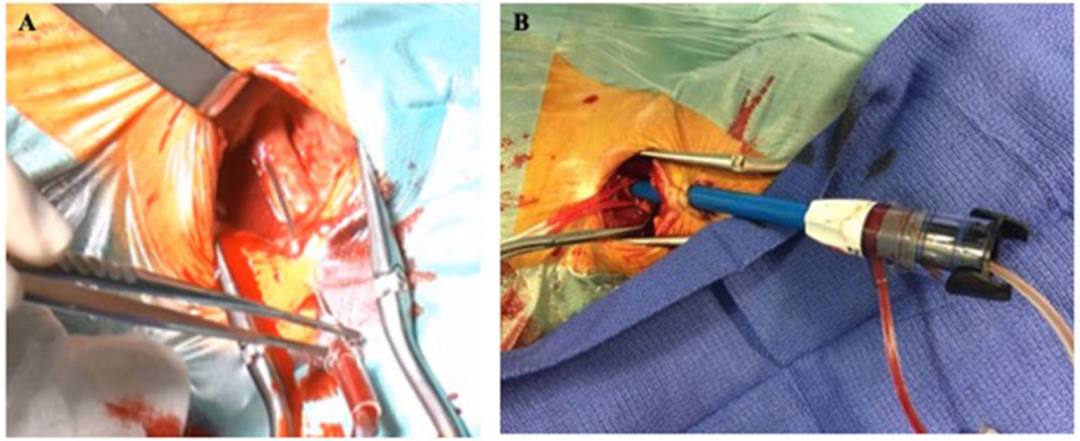

Overtchouk P et al. Interv Cardiol. 2018 Sep;13(3):145-150.
Perrin N et al. Front. Cardiovasc. Med. 8:747583.
Lanz J et al. EuroIntervention 2018;14:AB40-AB52

Anatomical constraints and limiting conditions

- Min. vessel dimaeter >5.5mm
- Calcification and tortuosity, plaque at risk of embolization
- Contralateral evaluation (circle of Willis perfusion?)

Specific considerations

- Short neck
- **Prior ipsilateral carotid artery intervention**
- **Stenosis or occlusion of contrlateral carotid artery or vertebral arteries**
- Anticipated difficult airway

Specific complications and disadvantages

- Complications of acccess preparation (nerve injury)
- Monitoring of cerebral perfusion required (rSO2)

- Similar outcomes to TF access in terms of mortality and morbidity in some trials

- French TAVI registry: 314 patients, Sapien 3, procedural success of 97%.
  - At 30-days: major bleeding: 4.1%, stroke or TIA :1.6% , mortality: 3.2%.

- Propensity-matched scoring between TC and TAx

  One-month mortality, one-month stroke/TIA and one-year mortality are similar with TAx-TAVR and TC-TAVR.

  Minor bleeding and main access haematoma were significantly more frequent with the TC access.

Overtchouk P et al. JACC Cardiovasc Interv. 2019;12(5):413-419.
Debry N et al. EuroIntervention. 2020;16(10):842-849.

Trans-subclavian/transaxillary Access (TS/TAx)

- Surgical or percutaneous
  - Specific technique for percutaneous (Doppler, safety wire,…)
- Left-side preferred
- CS+LA/GA: team dependent

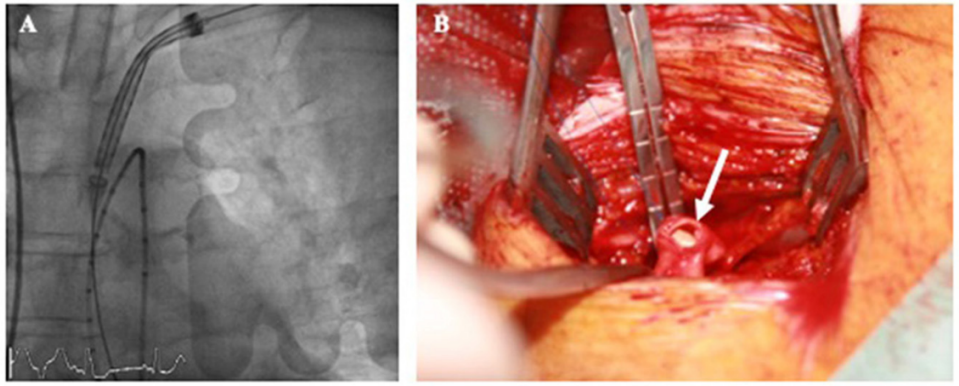

Overtchouk P et al. Interv Cardiol. 2018 Sep;13(3):145-150.
Perrin N et al. Front. Cardiovasc. Med. 8:747583.
Lanz J et al. EuroIntervention 2018;14:AB40-AB52

Anatomical constraints and limiting conditions

- Min. vessel dimaeter: 5.5mm (ratio sheath area/artery area <1.63)
- Calcification (take-off), tortuosity, **angulation with aortic arch**

Specific considerations

- **Patent internal mammary atery graft** (not absolute CI)
- Pacemaker
- Anatomical variants of aortic arch and course of brachial plexus

Specific complications and disadvantages

- More delicate vessel (more thin and elastic), more prone to complications (dissection, rupture)
- Risk of bleeding (manual compression ineffective)
- Risk of brachial plexus lesion

- Small propensity-matched comparison (TS: n=141 vs TF: n=141):

Similar rates of 2-y survival (74% vs 73,7%, p=0,78), major vascular complications (5 vs 7,8%, p=0,33) and life-threatening bleeding complications (7,8 vs 5,7%, p=0,48).

- Propensity score matching in STS/ACC TVT Registry:

TAx access had lower 30-day mortality (5.3% vs. 8.4%; $p < 0.01$), shorter lengths of intensive care unit and hospital stay, but a higher stroke rate (6.3% vs. 3.1%; $p < 0.05$) compared with TA and TAo access.

- Meta-analysis:
  - increased risk of stroke compared with the transfemoral approach (OR: 1,53, 95%CI: 1.05-2.22)
  - not associated with an increased risk of 30-day death, bleeding, or vascular complication when taking into account the confounding factors

- Fully perctuaneous technically feasible and safe :

Results percutaneous (100 patients): 30-d mortality 6%, 1-y mortality 15%, no major bleeding or stroke.

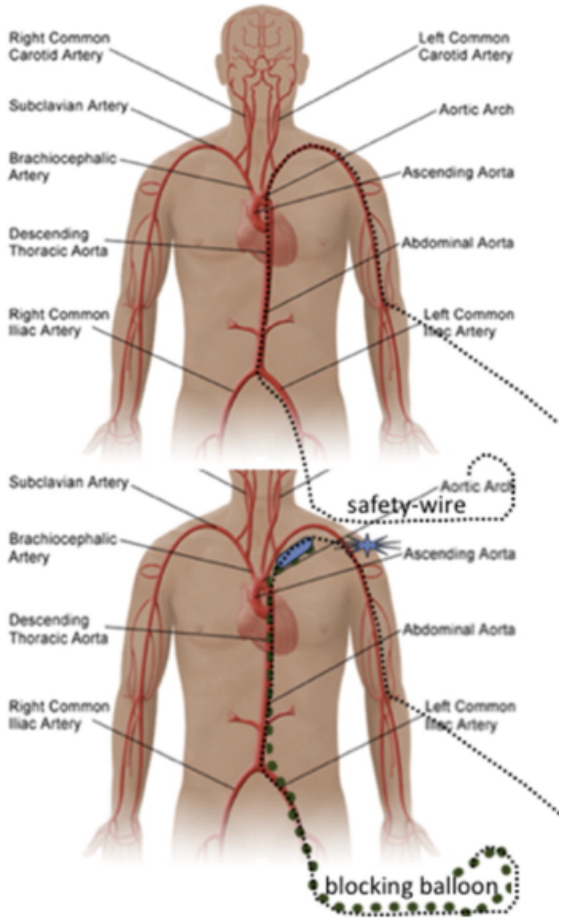

Petronio A et al. J Am Coll Cardiol. 2012;60(6):502-7.
Dahle T et al. JACC Cardiovasc Interv. 2019;12(7):662-669.
Faroux L et al. J Am Heart Assoc. 2020;9(19):e017460.
Schäfer U et al. Int J Cardiol. 2017;232:247-254.

Transcaval Access

- Experimental? : expert centers : inelegible for any other access, compatible anatomy
- Ergonomics of the TF access
- Large introducer sheath size
- Life-threatening/major bleeding, compatible anatomy (calcifications), use of occluder device, experience and skills
- First results: high rate of Life-threatening/major bleeding
- Encouraging Recent data

CENTRAL ILLUSTRATION Transcaval Access Technique for TAVR

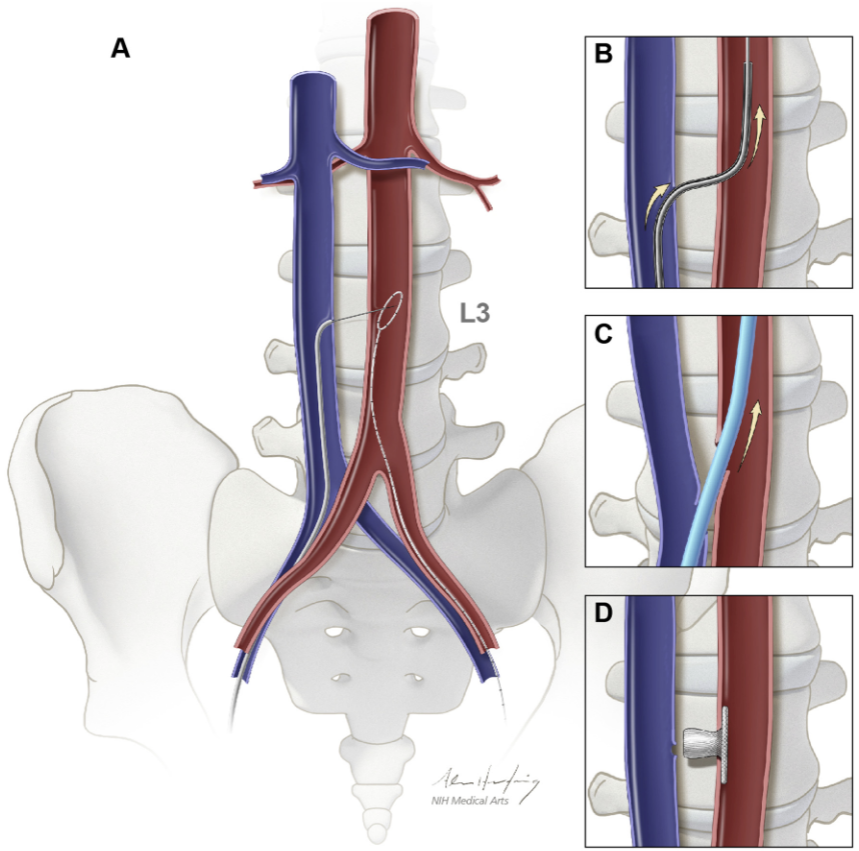

Greenbaum, A.B. et al. J Am Coll Cardiol. 2017;69(5):511–21.

(A) Transcaval access is obtained over an electrified guidewire directed from the inferior vena cava toward a snare in the abdominal aorta. **(B)** After delivering a microcatheter to exchange for a stiff guidewire, **(C)** the transcatheter heart valve introducer sheath is advanced from the femoral vein into the abdominal aorta for conventional transfemoral retrograde transcatheter aortic valve replacement (TAVR). **(D)** The aorto-caval access site is closed with a nitinol cardiac occluder. Courtesy of A. Hoofring, NIH Medical Arts Branch.

- **First experience:** high rate of Life-threatening/major bleeding
  - successful in 99 of 100 patients.
  - Access closure (nitinol cardiac occlude) in 98 of 99 patients; 1 covered stent.
  - Inpatient survival: 96%, 30-day survival: 92%.
  - VARC-2 life-threatening bleeding: 7%
  - Modified VARC-2 major vascular complications possibly related to transcaval access : 13%

- **Encouraging Recent data**

○ A Propensity-Weighted Analysis**:** 8 experienced centers - STS/ACC TVT between 2017 and 2020.
  - Transcaval TAVR : lower rates of stroke and similar bleeding compared with Tax
  - Both approaches had more complications than TF

○ 50 patients in 5 European centers
  - mean age of 78.7±8.0 years
  - high surgical risk profile (median STS risk score 6.1%, interquartile range 3.0-11.2%).
  - transcaval access successful in 49 out of 50 patients
  - device success in 94% of cases
  - Closure of the caval-aortic puncture site successful in all cases without need for emergent surgery.
  - 1 additional sealing of the aortic puncture site with a covered stent one day post TAVI due to a gradual haemoglobin drop
  - VARC-2-defined life-threatening bleeding 4%
  - Major vascular complications possibly related to transcaval access 10%

CENTRAL ILLUSTRATION: Key Outcomes After Transcaval Versus Transaxillary Access in Contemporary Practice

Transcaval vs Transaxillary Access for TAVR, N = 344

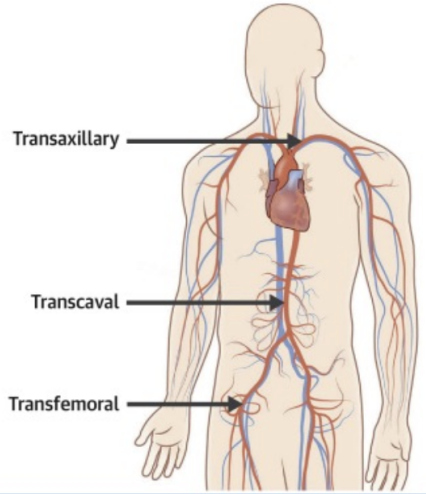

In-Hospital Events	Transcaval (n = 238)	Transaxillary (n = 106)	Transfemoral (n = 7,132)
Stroke or TIA	3% *	13%	2%
Bleeding †	10%	13%	4%
Death	4%	4%	1%
Discharge home without stroke/TIA	88% *	62%	90%

* $P < 0.001$ Transcaval vs Transaxillary
† Major or life-threatening bleeding (VARC-3 ≥ Type 2)

Lederman RJ, et al. J Am Coll Cardiol Intv. 2022;15(9):965-975.

Greenbaum A et al. J Am Coll Cardiol. 2017;69(5):511-521.
Lederman R et al. JACC Cardiovasc Interv. 2022;15(9):965-975.
Costa G et al. EuroIntervention. 2020;15(15):e1319-e1324

Algorithm for alternative approach selection

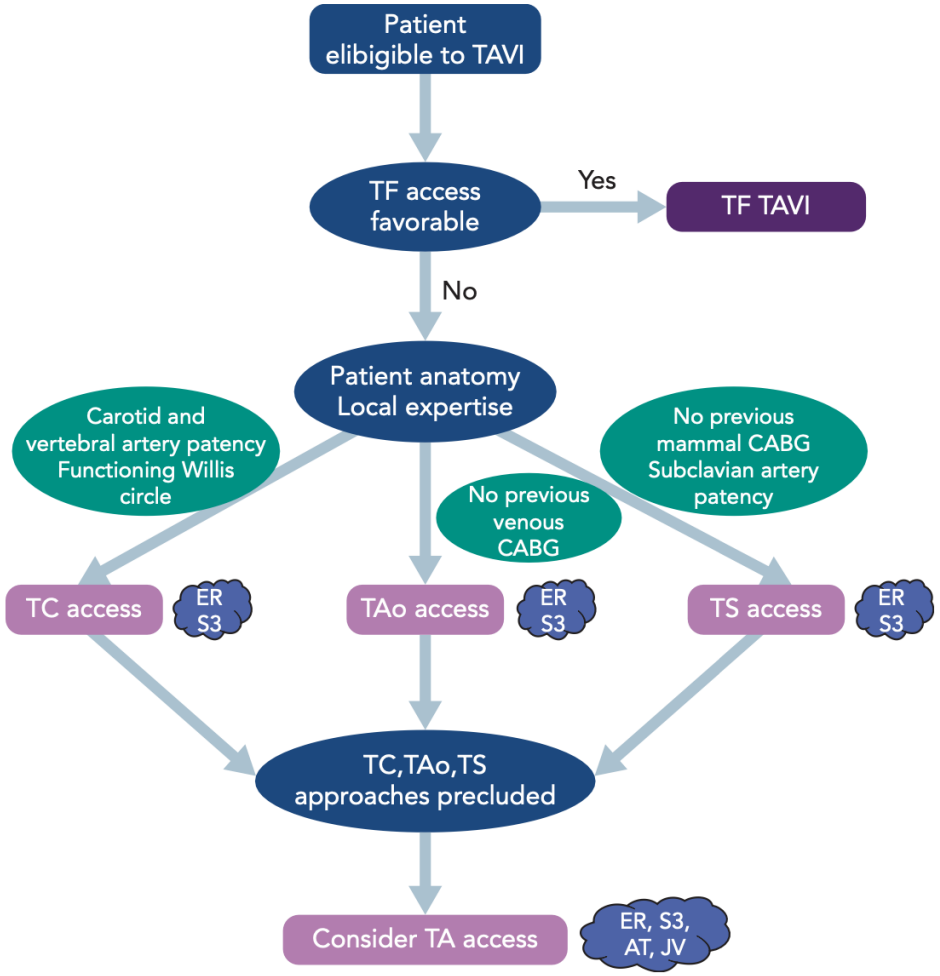

AT = ACURATE TA; JV = JenaValve; ER = Evolut R; S3 = SAPIEN 3; TA = transapical; TAo = transaortic; TC = transcarotid; TF = transfemoral; TS = trans-subclavian.

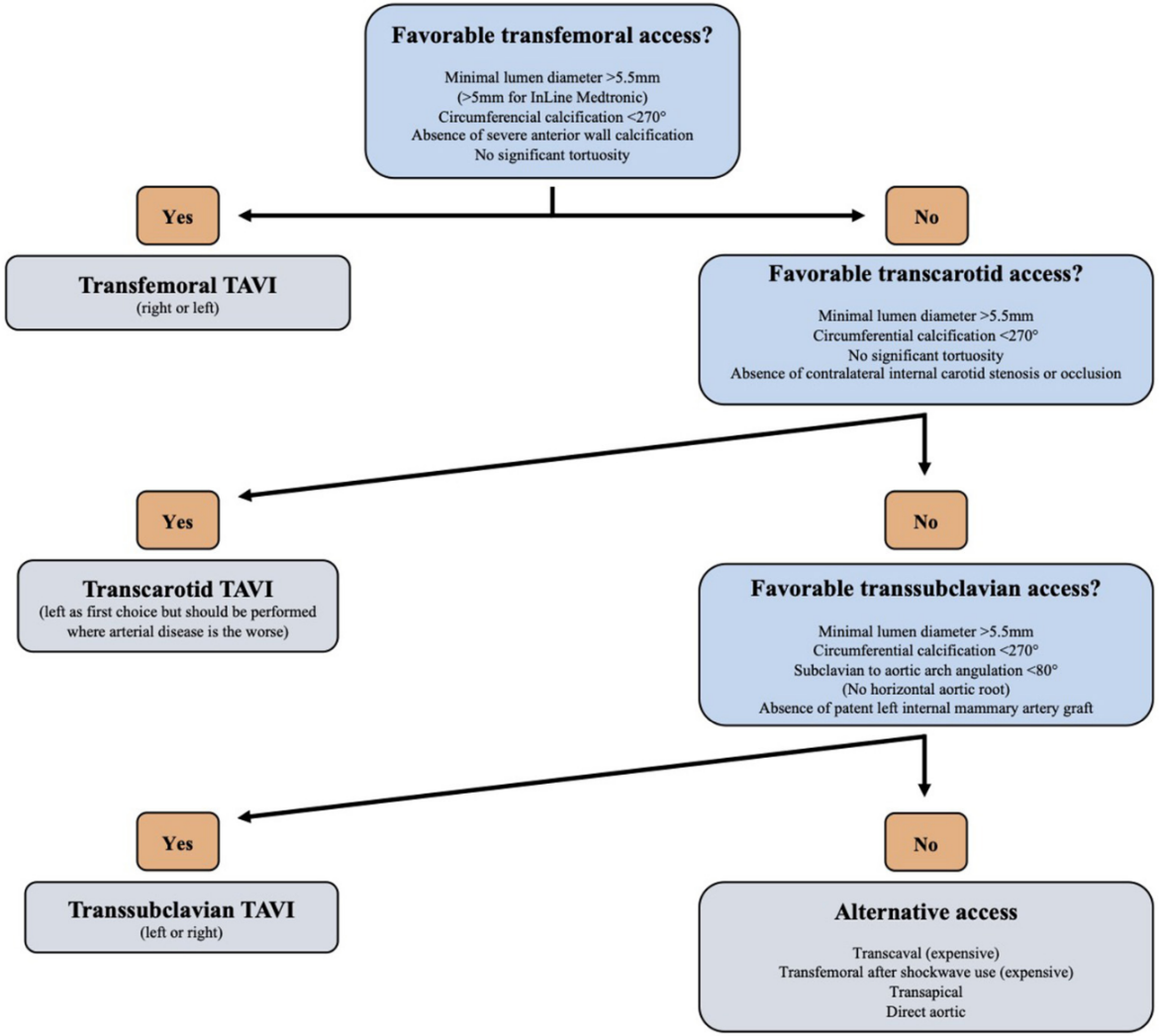

HOW

should we perform an alterntive access?

How?

- Careful selection – Pre-Procedural Imaging (MSCT)
- Technique: as we learned from TF
- Contralateral/ipsilateral Safety wire
- Careful Closure
- Angioplasty balloon, covered stent ready-for-use
- Secondary vascular access: radial access (?) (less complications, less stroke but crossover more challenging)
- Heparin reversal
- Surgical access if necessary
- Plan B (bail-out option in mind, surgery team)

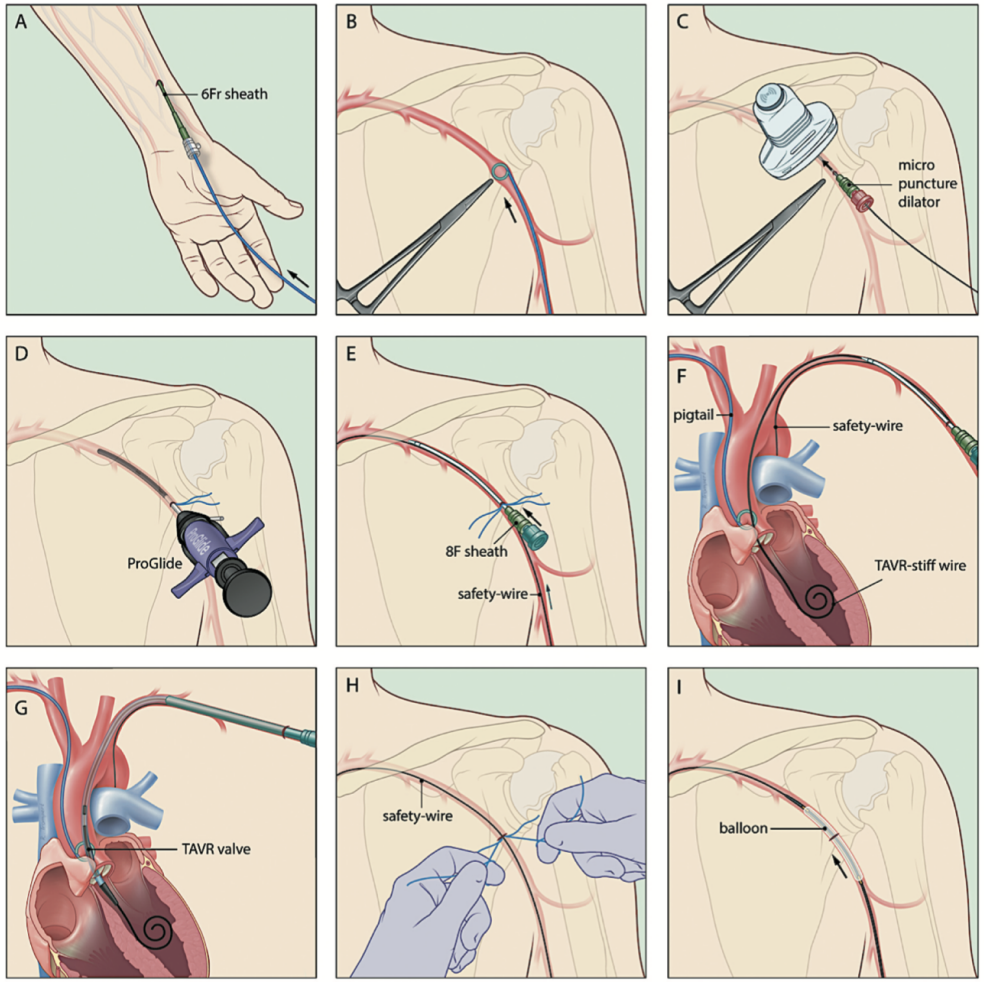

Wilkins B et al. Structural Heart 2021;5:79-84

CONCLUSION

- TF is to remain the favorite access
- Evolution of techniques and expertise allows more TF cases
- Pre-procedural imaging assessment by MSCT is key
- Selection of alternative routes depends mostly on the anatomy, patient characteristics and expertise
- More data needed on AA but TC and TAx show good results, Tcaval needs more data
- Less invasive access the better (fully percutaneous program?)

THANK YOU

EUROVALVE
CROWNE PLAZA LINATE
MILAN
SEPTEMBER
21&22,2023

Clinical Cases

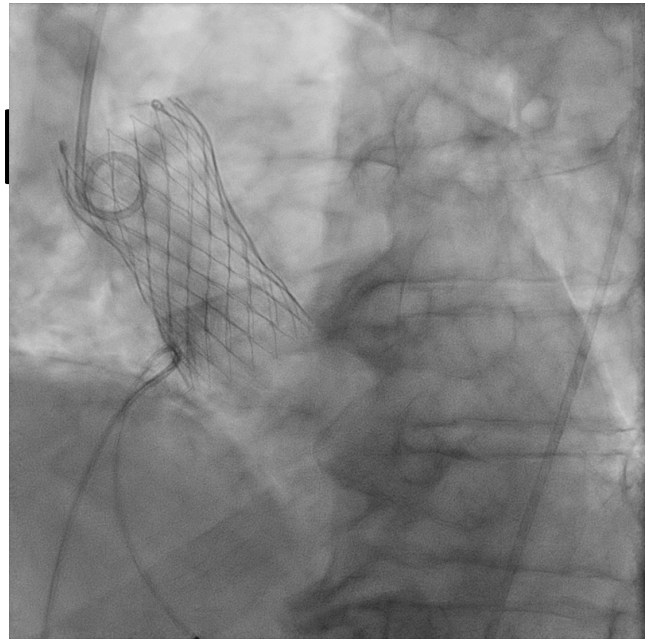

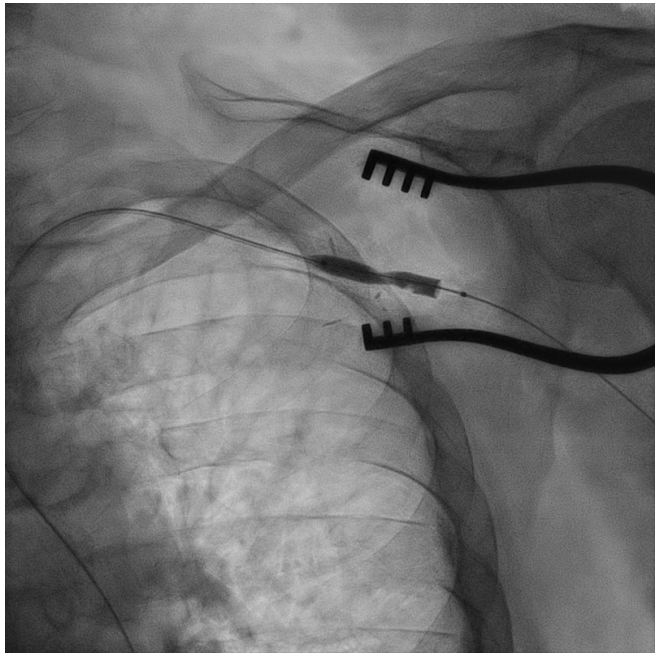
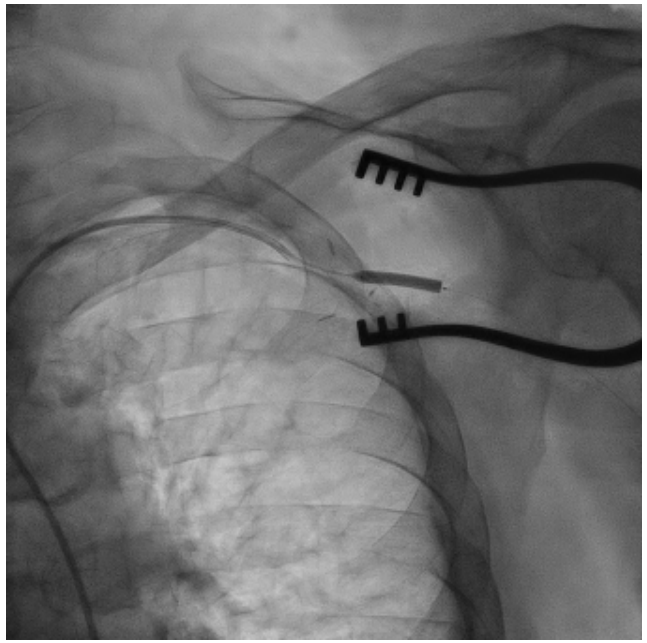
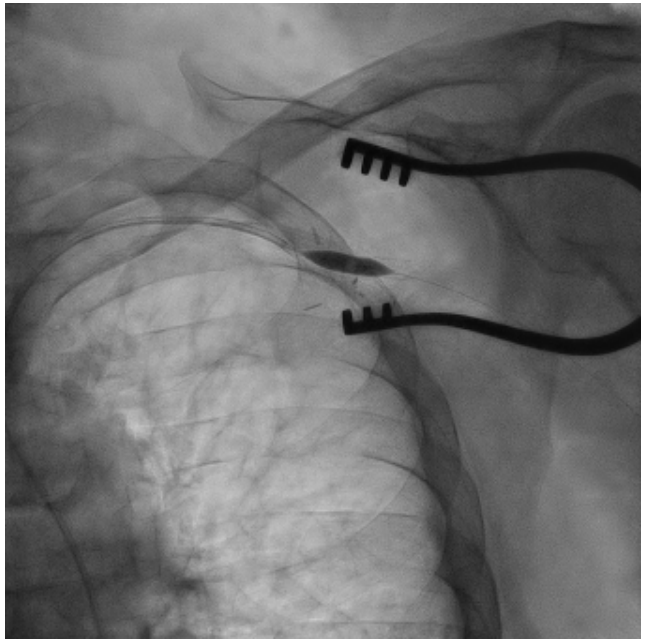
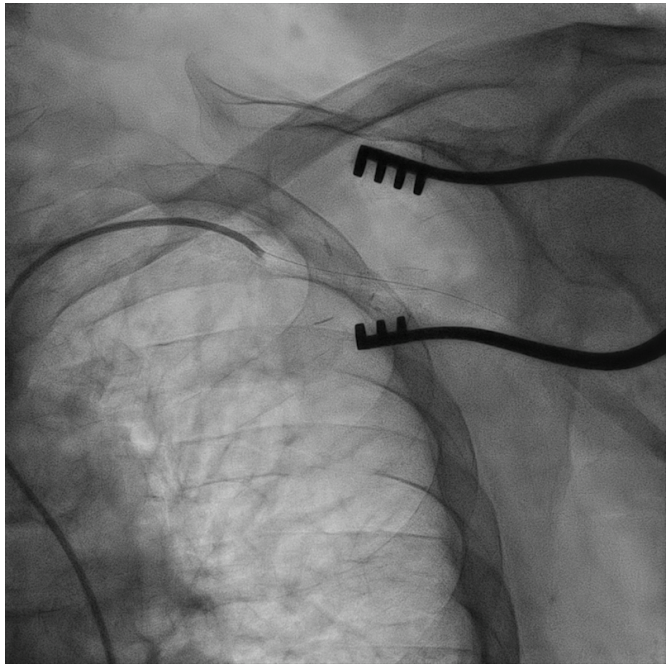




Ø 5.5 mm

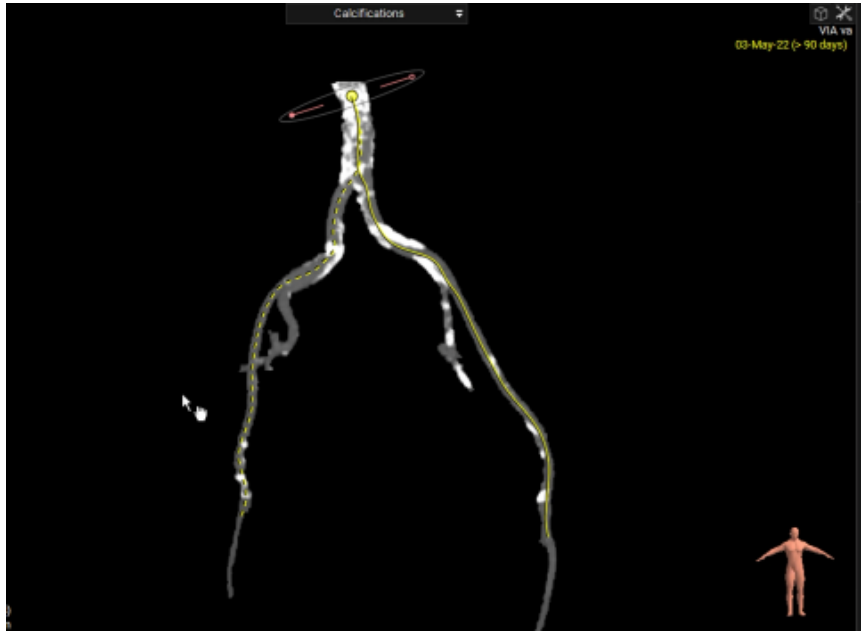
Calcifications
VIA va
03-May-22 (> 90 days)

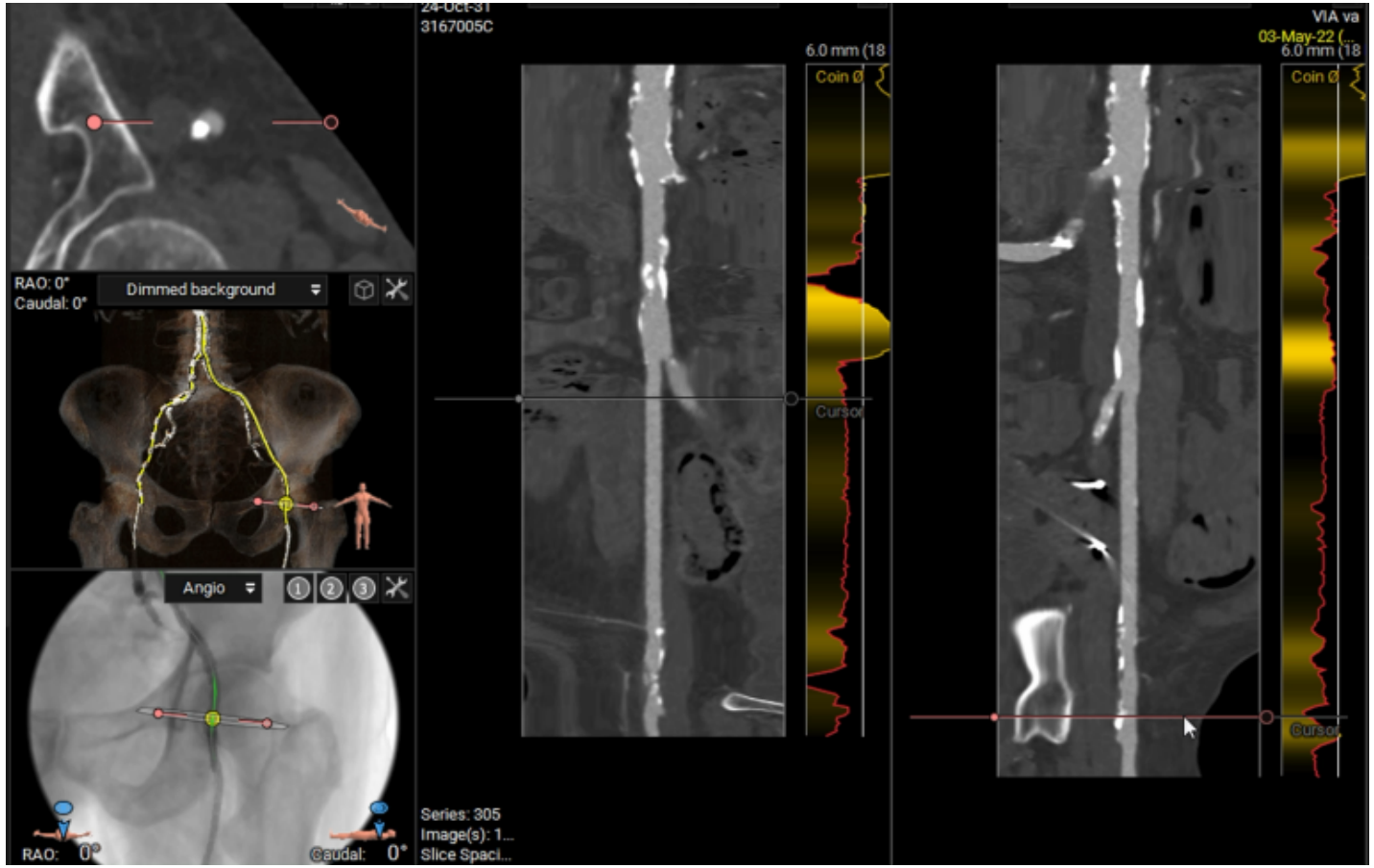
RAO: 0°
Caudal: 0°
Dimmed background
Angio
RAO: 0°
Caudal: 0°
24-Oct-31
3167005C
6.0 mm (18
Coin Ø
Cursor
Series: 305
Image(s): 1...
Slice Spaci...
VIA va
03-May-22 (...
6.0 mm (18
Coin Ø
Cursor

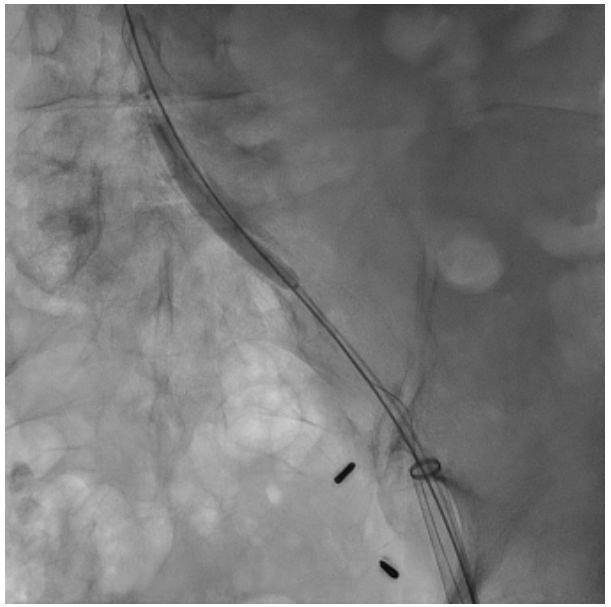
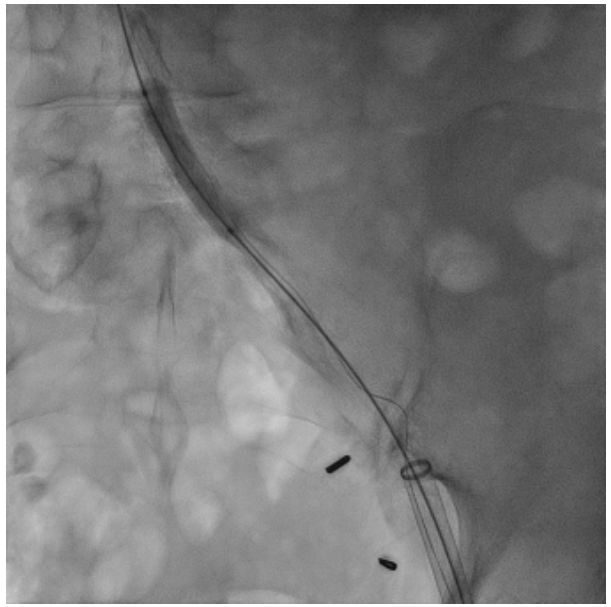
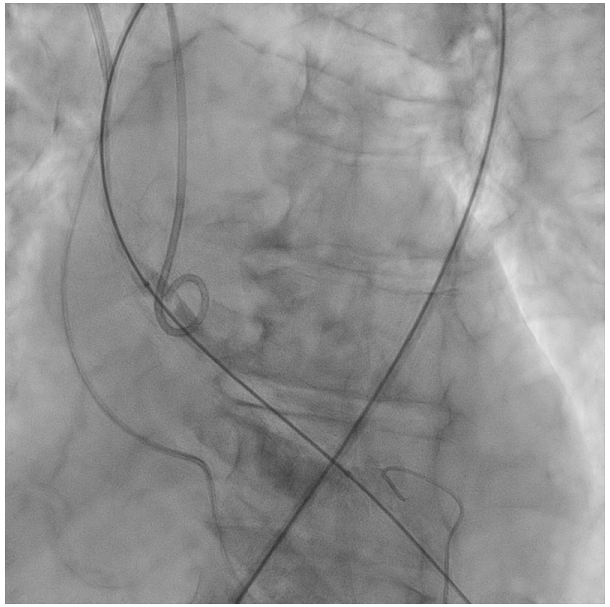
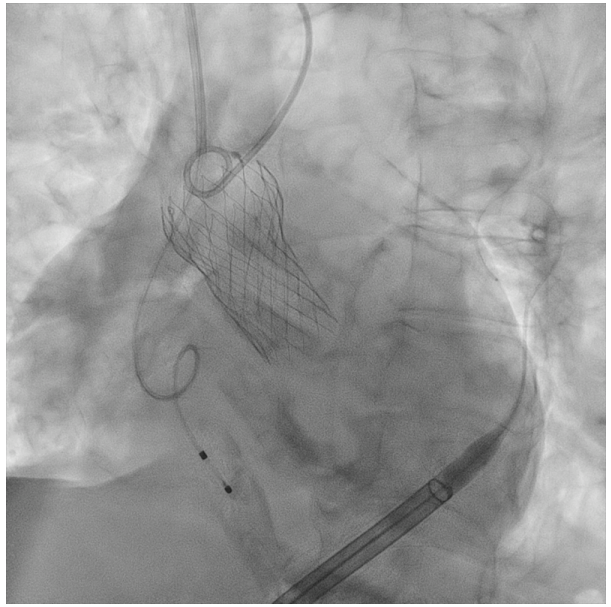
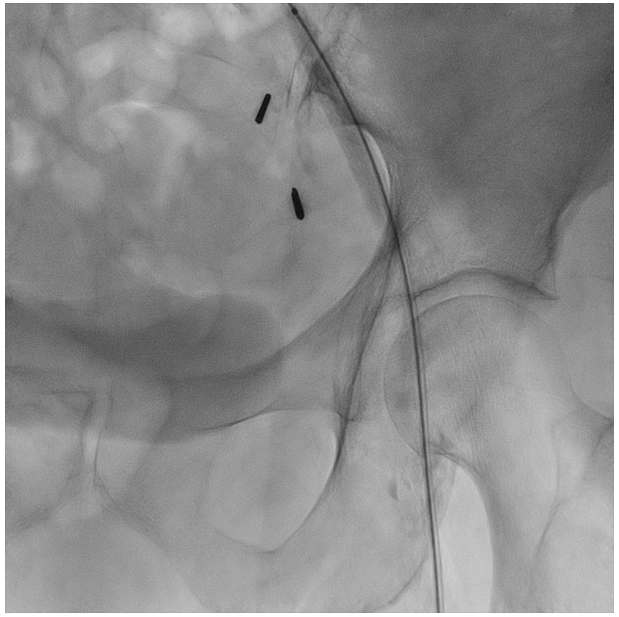
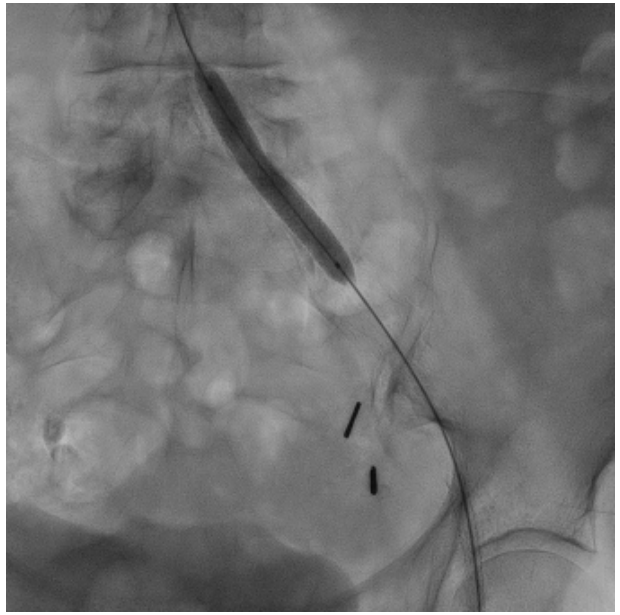
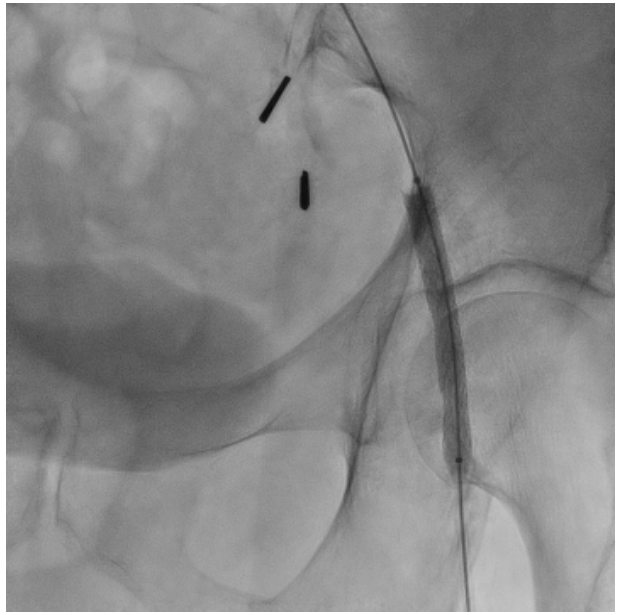


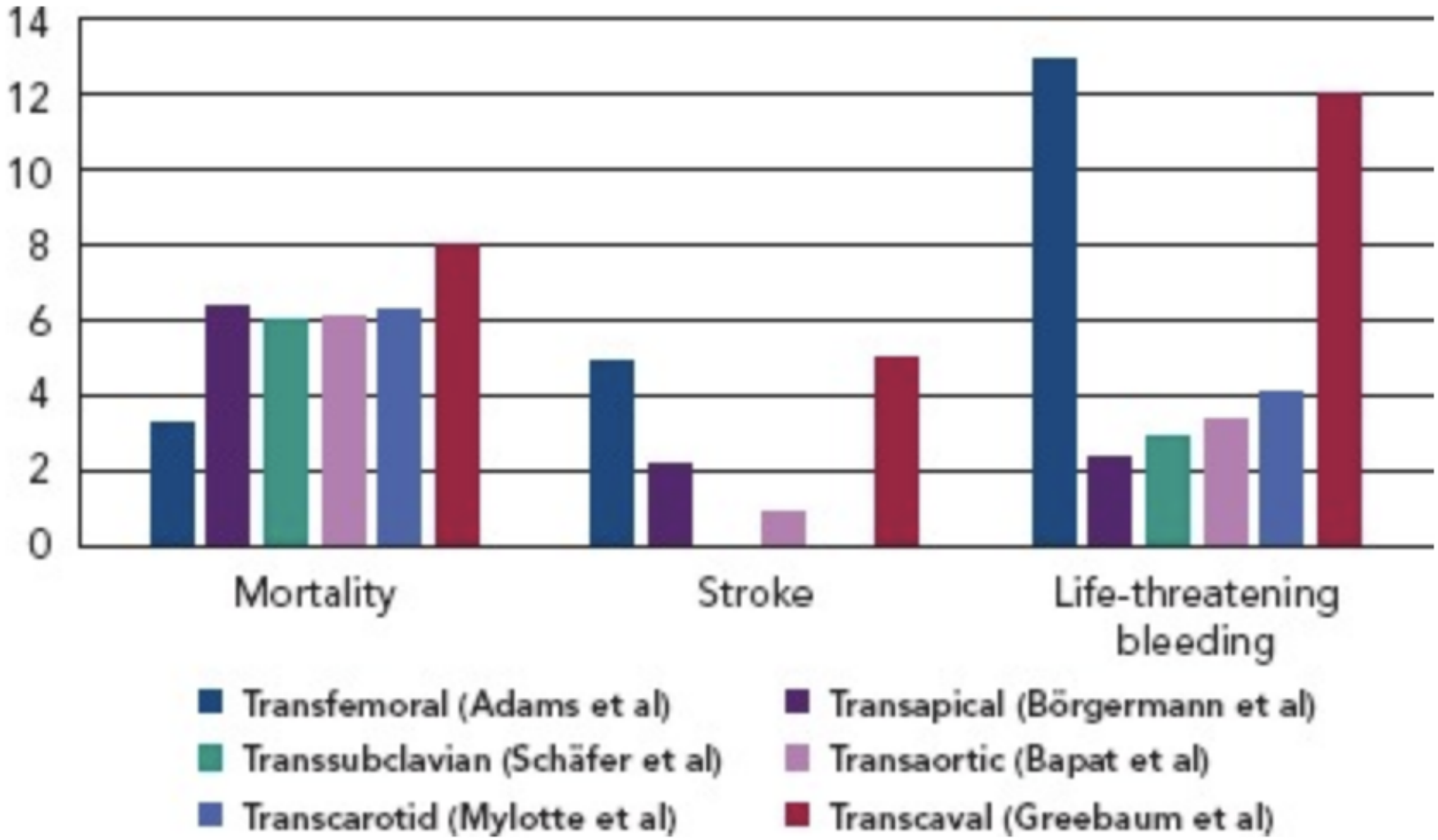
14
12
10
8
6
4
2
0
Mortality
Stroke
Life-threatening bleeding
Transfemoral (Adams et al)
Transapical (Börgermann et al)
Transsubclavian (Schäfer et al)
Transaortic (Bapat et al)
Transcarotid (Mylotte et al)
Transcaval (Greebaum et al)

Back-up slides

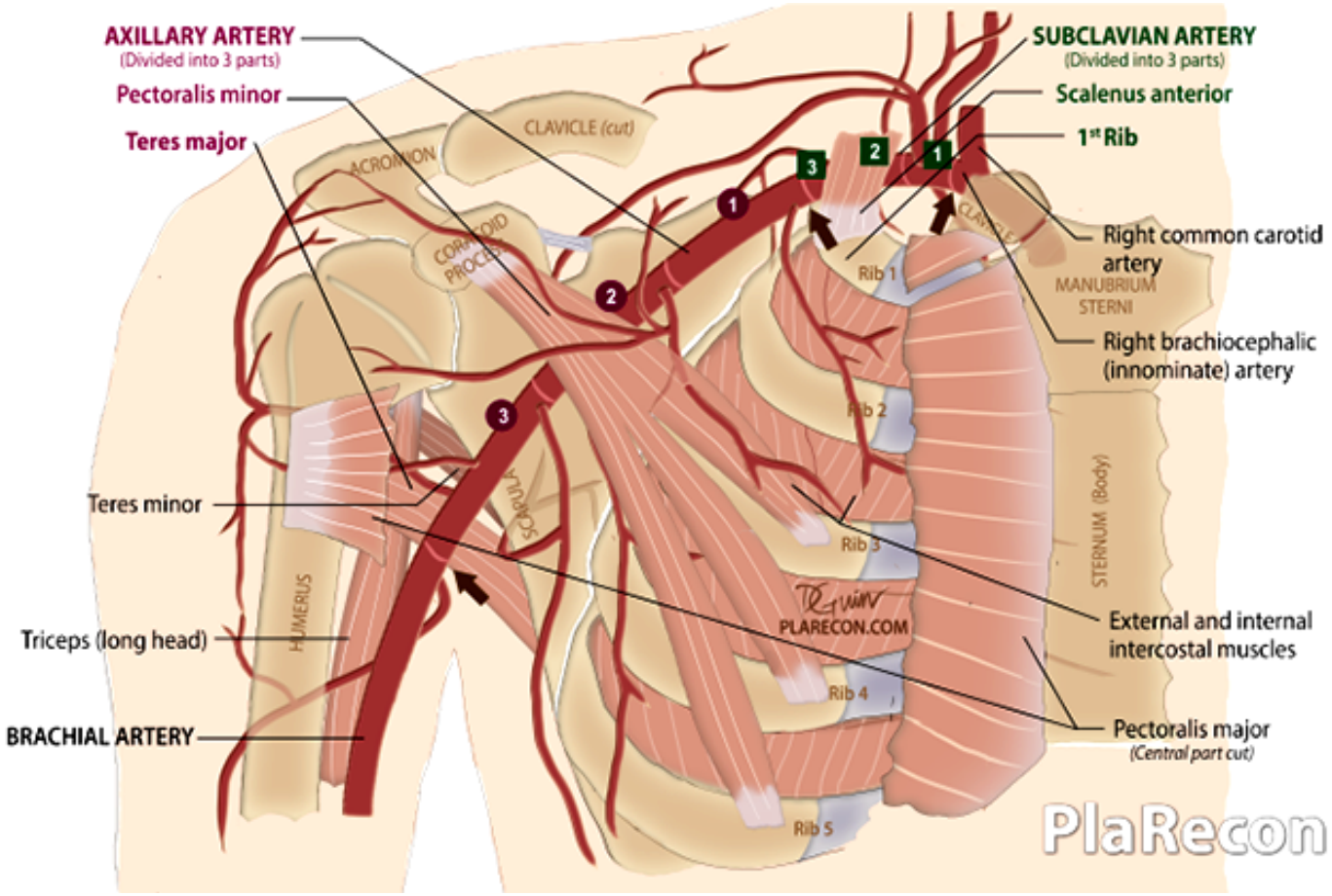

Anatomically subclavian artery (SCA) is defined from its origin to the lateral edge of the first rib.

The axillary artery is anatomically defined by the lower margin of the first rib proximally and lateral edge of the teres major muscle distally.

The ideal site for percutaneous axillary access is its first segment, just proximal to the thoracoacromial branch.

This site is chosen based on invariant position and absence of overlying nerves or veins. Besides this, some authors argue that, in this position, the axillary artery could be easily manually compressed against the second rib

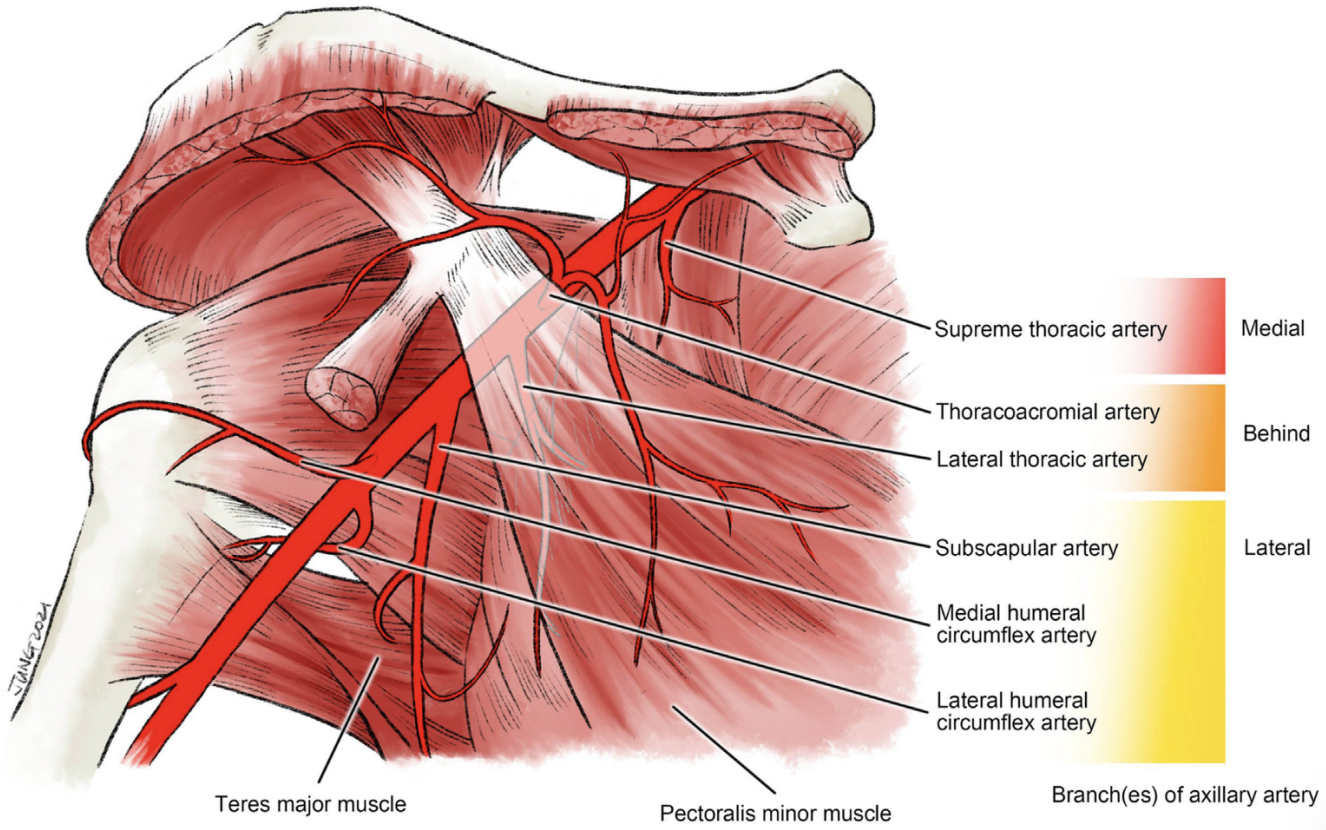

FIGURE 5.8 Branches of the right axillary artery.

FIGURE 3 Representative Transcaval TAVR Procedure

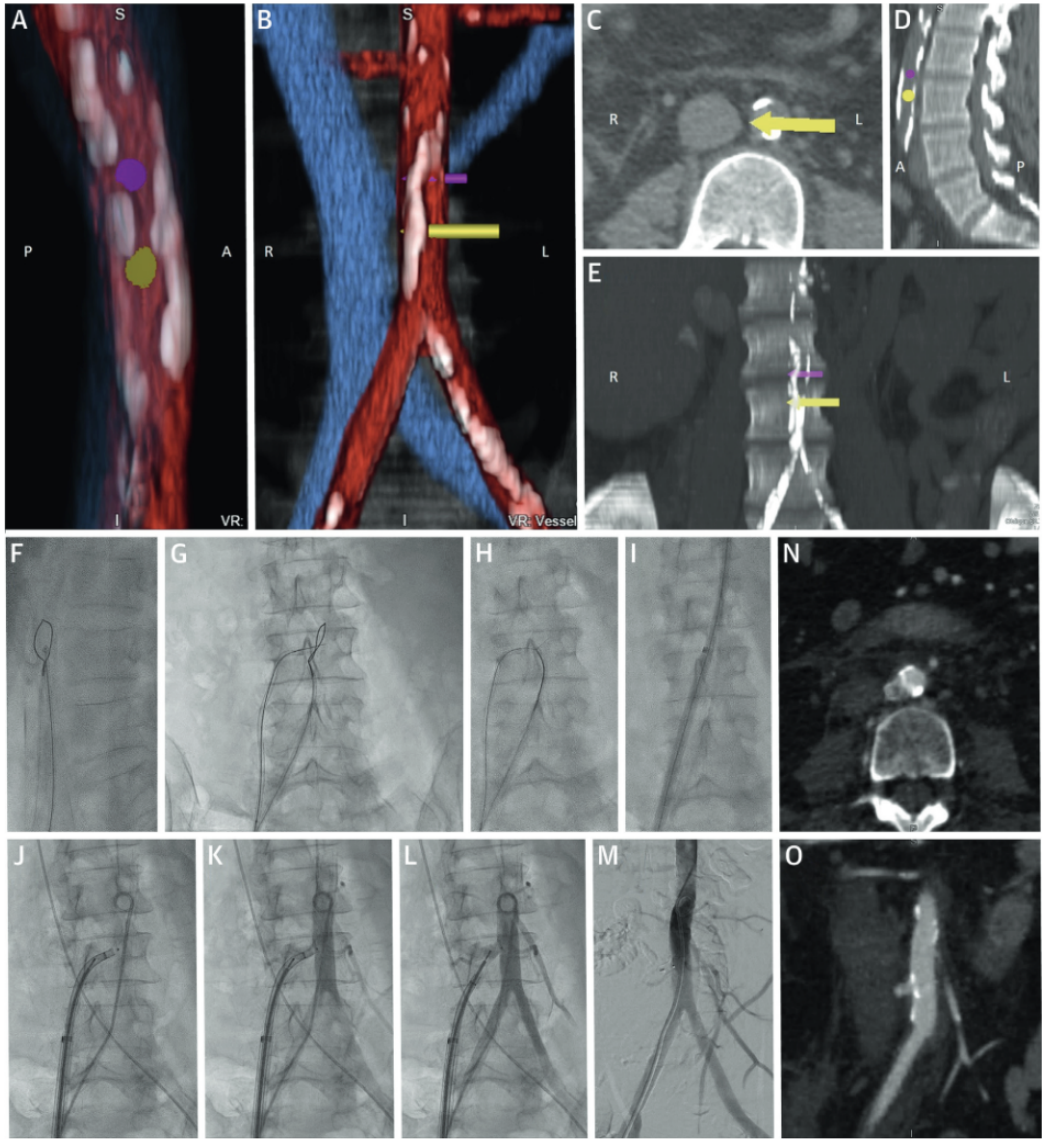

(A to E) A suitable target **(yellow arrow)** is identified on computed tomography (CT) and displaced in **(C)** axial reconstruction to show the crossing point **(yellow arrow)**, **(D)** sagittal reconstruction to show the lumbar level, and **(E)** coronal thick-slab projection to simulate fluoroscopy. **(F)** Under fluoroscopy, the transvenous crossing catheter is aligned with the aortic snare in a lateral projection; **(G)** the guidewire is electrified during advancement into the aorta and **(H)** then snared and exchanged for a stiff guidewire. **(I)** The transcatheter heart valve (THV) sheath is advanced from the femoral vein into the aorta. **(J to L)** After transcatheter aortic valve replacement (TAVR), a nitinol cardiac occluder device is positioned across the aortic wall. **(M)** In this case, completion angiography shows complete occlusion of the aorto-caval fistula. **(N and O)** Pre-discharge CT shows the device in position with a small retroperitoneal hematoma and an occluded tract. An alternative target is depicted with a **purple arrow**.

FIGURE 2 Crossing Equipment

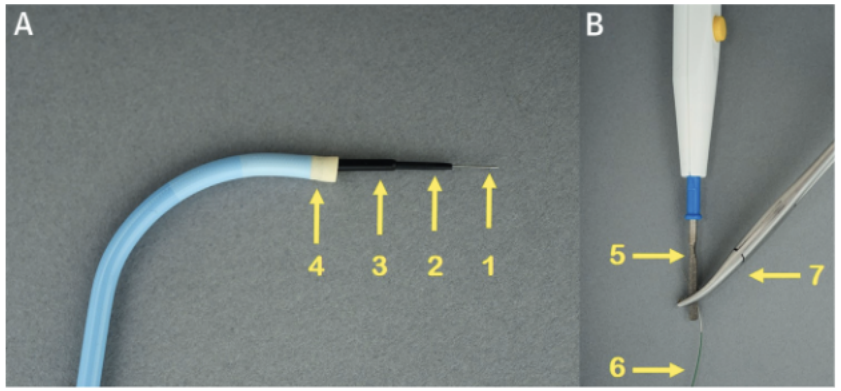

(A) Coaxial crossing system consisting of **(1)** 0.014-inch guidewire inside of a **(2)** Piggyback 0.035-inch wire convertor inside of a **(3)** braided microcatheter, inside of a **(4)** 55-cm guiding catheter. **(B)** An electrosurgery pencil **(5)** is connected to the backend of the 0.014-inch guidewire **(6)** using a hemostatic forceps **(7)**.

CENTRAL ILLUSTRATION Transcaval Access Technique for TAVR

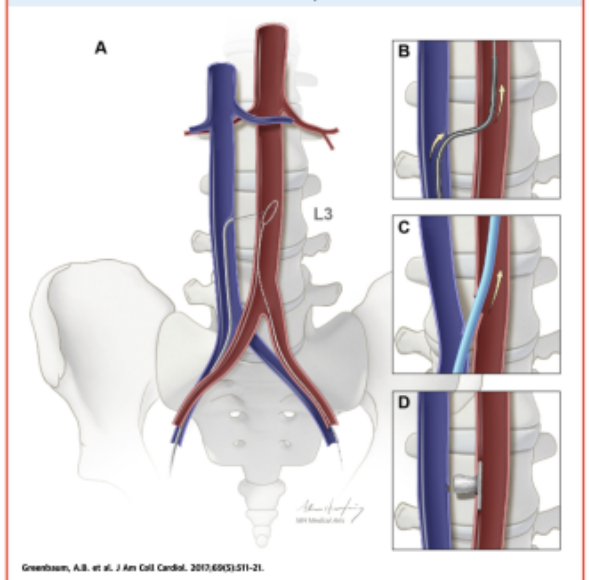

(A) Transcaval access is obtained over an electrified guidewire directed from the inferior vena cava toward a snare in the abdominal aorta. **(B)** After delivering a microcatheter to exchange for a stiff guidewire, **(C)** the transcatheter heart valve introducer sheath is advanced from the femoral vein into the abdominal aorta for conventional transfemoral retrograde transcatheter aortic valve replacement (TAVR). **(D)** The aorto-caval access site is closed with a nitinol cardiac occluder. Courtesy of A. Hoofring, NIH Medical Arts Branch.

FIGURE 1 Proposed Mechanism of Hemodynamic Stability After Transcaval Access Using Permeable Nitinol Occluder Devices

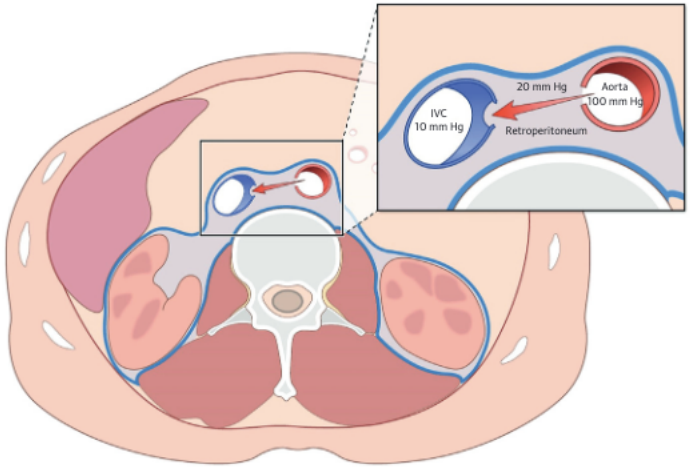

Higher pressure in the relatively confined retroperitoneal space exceeds venous pressure **(inset)** and causes aortic blood to return to the venous circulation through a nearby hole in the inferior vena cava (IVC) **(inset)**. The result is aortocaval fistula rather than hemodynamic collapse. Courtesy of A. Hoofring, NIH Medical Arts Branch.

CENTRAL ILLUSTRATION **Transcaval Aortic Access and Closure**

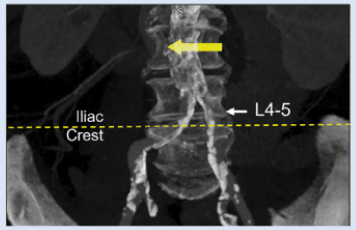

Permissive transcaval physiology

- Retroperitoneal pressure > venous
- Aortic bleeding decompresses into nearby IVC hole

CT planning

- Calcium-free target window
- Without interposed bowel
- Away from aortic branches
- Orthogonal fluoroscopic projection angles

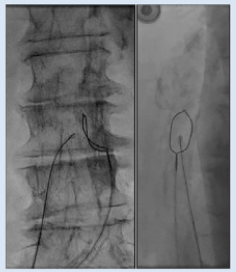

Electrosurgical guidewire traversal

- Coaxial crossing system
- Pre-position snare in aorta
- Confirm orientation in orthogonal projections
- Brief electrosurgical wire advancement
- Ensnare and exchange for rigid guidewire and TAVR introducer

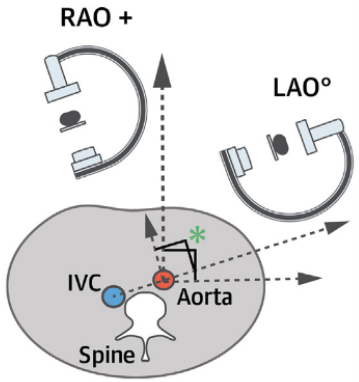

* Orthogonal projections

Transcaval tract closure

- Heparin reversal with protamine
- Prepare for bailout
- Deflectable sheath turns nitinol occluder sideways
- Fixation is from occluder neck not disc
- Release device

Interpret closure aortogram

- Troubleshooting (residual fistula is acceptable; extravasation warrants additional maneuvers)
- Balloon aortic tamponade or bailout covered stent if needed

Lederman RJ, et al. J Am Coll Cardiol Intv. 2023;16(4):371-395.

Red arrow indicates nitinol occluder device in place. CT = computed tomographic; IVC = inferior vena cava; LAO = left anterior oblique; RAO = right anterior oblique; TAVR = transcatheter aortic valve replacement.

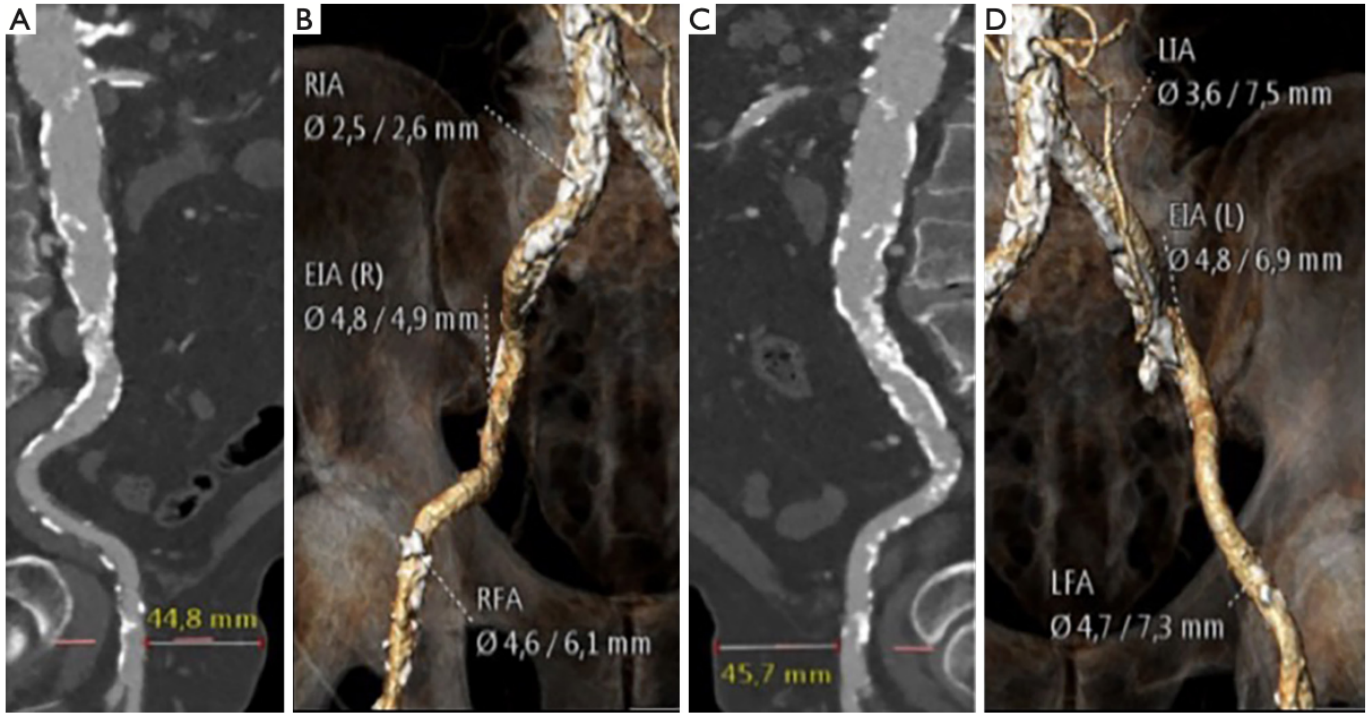

Figure 2 Severe and diffuse calcification, tortuosity and atherosclerotic disease represent unfavourable features for TAVI. TAVI, transcatheter aortic valve implantation.

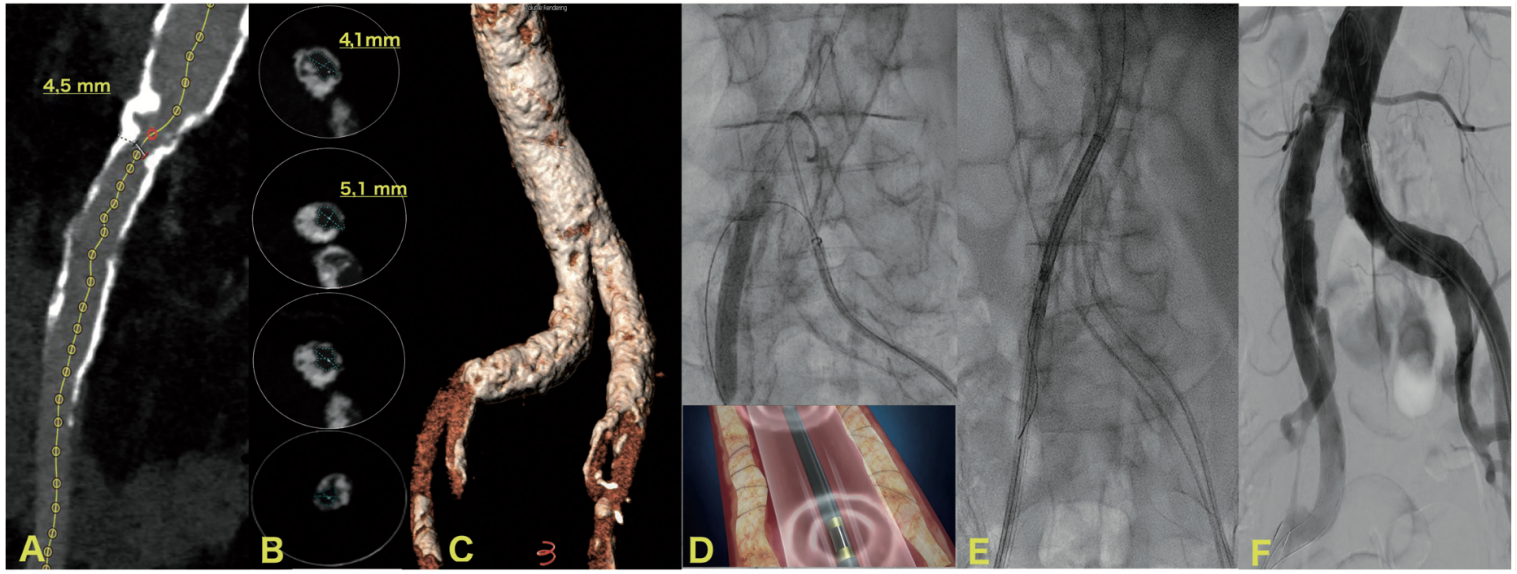

Di Mario C, Chiriatti N, Stolcova M, Meucci F, Squillantini G. Lithotripsy-assisted transfemoral aortic valve implantation. Eur Heart J. 2018 Jul 21;39(28):2655. doi: 10.1093/eurheartj/ehy021. PMID: 29420723.

Pascual I, Carro A, Avanzas P, Hernández-Vaquero D, Díaz R, Rozado J, Lorca R, Martín M, Silva J, Morís C. Vascular approaches for transcatheter aortic valve implantation. J Thorac Dis. 2017 May;9(Suppl 6):S478-S487. doi: 10.21037/jtd.2017.05.73. PMID: 28616344; PMCID: PMC5462718.

TRANSFEMORAL		
ILIOFEMORAL COMPLICATIONS		**AORTIC COMPLICATIONS**
Dissection Rupture Access site infection Access site bleeding	Stenosis/Thrombosis/Occlusion Artery avulsion Pseudoaneurysms Failed percutaneous closure	Aortic aneurysm Aortic rupture Aortic dissection Retroperitoneal hemorrahage
TRANSAPICAL	**TRANSAXILLARY**	**TRANSAORTIC**
Apical puncture bleeding Myocardial tears Apical scarring Blood flow obstruction (LAD) Aneurysm formation Chronic pain	Subclavian artery thrombosis Subclavian artery dissection Subclavian artery stenosis	Tearing of the aorta Deep wound infection Mediastinitis RIMA graft injury Right ventricle laceration IC artery pseudoaneurysm

Figure 1 TAVI-related major vascular complications according to access routes. TAVI, transcatheter aortic valve implantation; LAD, left anterior descendent; RIMA, right internal mammary artery; IC, intercostals.

Reviews, studies,…

- Banks A, Gaca J, Kiefer T. Review of alternative access in transcatheter aortic valve replacement. Cardiovasc Diagn Ther. 2020 Feb;10(1):72-82. doi: 10.21037/cdt.2019.10.01. PMID: 32175229; PMCID: PMC704

- Pour-Ghaz I, Raja J, Bayoumi M, Manolukas T, Khouzam RN, Ibebuogu UN. Transcatheter aortic valve replacement with a focus on transcarotid: a review of the current literature. Ann Transl Med. 2019 Sep;7(17):420. doi: 10.21037/atm.2019.07.11. PMID: 31660319; PMCID: PMC6787377.4091.

- Abraham B, Sous M, Sedhom R, Megaly M, Roman S, Sweeney J, Alkhouli M, Pollak P, El Sabbagh A, Garcia S, Goel SS, Saad M, Fortuin D. Meta-Analysis on Transcarotid Versus Transfemoral and Other Alternate Accesses for Transcatheter Aortic Valve Implantation. Am J Cardiol. 2023 Apr 1;192:196-205. doi: 10.1016/j.amjcard.2023.01.023. Epub 2023 Feb 21. PMID: 36821875.

- Kindzelski B, Mick SL, Krishnaswamy A, Kapadia SR, Attia T, Hodges K, Siddiqi S, Lowry AM, Blackstone EH, Popovic Z, Svensson LG, Unai S, Yun JJ. Evolution of Alternative-access Transcatheter Aortic Valve Replacement. Ann Thorac Surg. 2021 Dec;112(6):1877-1885. doi: 10.1016/j.athoracsur.2021.02.018. Epub 2021 Feb 27. PMID: 33647251.

- Chamandi C, Abi-Akar R, Rodés-Cabau J, Blanchard D, Dumont E, Spaulding C, Doyle D, Pagny JY, DeLarochellière R, Lafont A, Paradis JM, Puri R, Karam N, Maes F, Rodriguez-Gabella T, Chassaing S, Le Page O, Kalavrouziotis D, Mohammadi S. Transcarotid Compared With Other Alternative Access Routes for Transcatheter Aortic Valve Replacement. Circ Cardiovasc Interv. 2018 Nov;11(11):e006388. doi: 10.1161/CIRCINTERVENTIONS.118.006388. PMID: 30571205.

- Bob-Manuel T, Almusawi H, Rezan T, Khaira H, Akingbola A, Nasir A, Soto JT, Jenkins J, Ibebuogu UN. Efficacy and Safety of Transcarotid Transcatheter Aortic Valve Replacement: A Systematic Review. Cardiovasc Revasc Med. 2020 Jul;21(7):917-926. doi: 10.1016/j.carrev.2019.12.012. Epub 2019 Dec 10. PMID: 31882332.

- Palmerini T, Saia F, Kim WK, Renker M, Iadanza A, Fineschi M, Bruno AG, Ghetti G, Vanhaverbeke M, Søndergaard L, De Backer O, Romagnoli E, Burzotta F, Trani C, Adrichem R, Van Mieghem NM, Nardi E, Chietera F, Orzalkiewicz M, Tomii D, Pilgrim T, Aranzulla TC, Musumeci G, Adam M, Meertens MM, Taglieri N, Marrozzini C, Alvarez Covarrubias HA, Joner M, Nardi G, Di Muro FM, Di Mario C, Loretz L, Toggweiler S, Gallitto E, Gargiulo M, Testa L, Bedogni F, Berti S, Ancona MB, Montorfano M, Leone A, Savini C, Pacini D, Gmeiner J, Braun D, Nerla R, Castriota F, De Carlo M, Petronio AS, Barbanti M, Costa G, Tamburino C, Leone PP, Reimers B, Stefanini G, Sudo M, Nickenig G, Piva T, Scotti A, Latib A, Vercellino M, Porto I, Codner P, Kornowski R, Bartorelli AL, Tarantini G, Fraccaro C, Abdel-Wahab M, Grube E, Galié N, Stone GW. Vascular Access in Patients With Peripheral Arterial Disease Undergoing TAVR: The Hostile Registry. JACC Cardiovasc Interv. 2023 Feb 27;16(4):396-411. doi: 10.1016/j.jcin.2022.12.009. Epub 2023 Jan 18. PMID: 36858659.

- Aurélien Villecourt, Laurent Faroux, Alexandre Muneaux, Sophie Tassan-Mangina, Virginie Heroguelle, Anne Poncet, Pierre Nazeyrollas, Vito Giovanni Ruggieri, Damien Metz,. Comparison of clinical outcomes after transcarotid and transsubclavian versus transfemoral transcatheter aortic valve implantation: A propensity-matched analysis,Archives of Cardiovascular Diseases,Volume 113, Issue 3,020,Pages 189-198,